

ELECTROCARDIOGRAPHIC CHANGES IN ACUTE METHANOL POISONING*

D. K. Hazra,** H. C. Seth,*** K. S. Mathur,† P. K. Wahal,†† V. Prakash,†††
B. B. Maheshwari‡ and Sanjaya Tandan‡‡

SUMMARY Electrocardiographic changes observed in 11 cases of acute methyl alcohol poisoning including 4 fatal cases have been described. right atrial overload; clockwise rotation and right ventricular strain were the chief electrocardiographic manifestations. The time course of these changes and the possible mechanism have been discussed.

Methanol poisoning occurs not infrequently owing to the sale of adulterated liquor or the consumption of methylated spirit. During an outbreak of methanol poisoning at Agra, certain characteristic electrocardiographic changes were observed which do not appear to have been reported in literature and they form the subject of the present communication.

CASE REPORT

During the period between 8-10-1968 to 10-10-1968 an outbreak of methyl alcohol poisoning occurred at Agra, due to the sale of adulterated country liquor; 14 of whom were admitted to Emergency Department of Sarojini Naidu Hospital or to the Eye Hospital (Table 1).

The first 3 cases were admitted in profound cardiac shock and expired in less than an hour (case 1, 2 and 3). Electrocardiograms were

not recorded in these cases but in all subsequent admissions they were recorded within an hour of admission and repeated periodically during their hospital stay. Apart from first 3 cases in whom E.C.G. could not be recorded, a characteristic pattern of alteration in E.C.G. was observed in 10 out of the remaining 11 cases. Amongst these 10 cases, 4 died and one absconded. In the remaining 5 cases, serial electrocardiograms showed the reversal electrocardiographic changes of the first E.C.G. *pari passu* with clinical recovery.

Table 2 analyses the E.C.G. changes observed in 10 cases. It is noteworthy that these 10 cases included 3 cases (Case 10, 11 and 13) who presented to the eye hospital with blindness alone and without cardiovascular symptomatology or shock. One other was admitted only with abdominal pain (Case 8). As regards the other case, 3 were comatose (Case 4, 5, 6) on admission and the remaining 3 were in shock (Case 7, 13, 14).

Right atrial overload in the form of tall peaked 'P' wave was observed in all except one (Case 12), the voltage of P varying from 3.5 mv to 4.5 mv in lead II. There was evidence of marked clockwise rotation (Transitional zone in V_6 or beyond) in 9 cases. Right ventricular strain in the form of tall R wave in right precordial leads were observed in 8 cases (RV_1 varying from 7 to 17 milli-volts in these cases). Supraventricular Tachycardia was observed in one case and sinus tachycardia in other 9 cases. Right axis deviation more than 110° was observed in 2 cases (Case 4 & 9). Incomplete Right Bundle Branch Block were observed in one case (No. 11) which disappeared in subsequent E.C.G. 4 days after poisoning. Complete Right Bundle Branch Block was observed in 1 case but this did not revert (Fig. 1).

Figs. 1, 2, 3 exemplify the pattern of changes observed and their regression in serial ECGs. It is observed that in some cases P normalization was followed by a decrease in amplitude of R

*From the Postgraduate Department of Medicine, S.N. Medical College, Agra.

**Lecturer in Medicine.

***Resident Medical Officer.

†Professor & Head of the Postgraduate Department of Medicine.

††Professor of Clinical Medicine.

†††Lecturer in Medicine.

‡Research Officer.

‡‡Research Scholar.

TABLE 1

Name	Age & Sex	Quantity of alcohol consumed in litres	Time interval preceding admission	Presenting symptoms	Electrocardiographic changes	Clinical Course
1. R.S.	30 HM	0.25	10 Hrs.	Coma, Shock	Not recorded	Expired within 20 mts.
2. K.S.	40 HM	0.5	6 Hrs.	Vomiting, Shock	-do-	Expired within 40 mts.
3. H.	30 M	0.5	7 Hrs.	Coma, vomiting	-do-	Expired within 30 mts.
4. P.	50 M	0.25	12 Hrs.	Coma	Changes present	Expired within 1 hr.
5. B.D.	40 M	0.25	12 Hrs.	Coma, vomiting	-do-	Expired within 4 hrs.
6. K.L.	50 M	0.25	18 Hrs.	Coma	-do-	Expired within 3 hrs.
7. J.L.	36 M	0.25	24 Hrs.	Abdominal pain, vomiting, Stupor, bilateral blindness	-do-	Expired within 4 hrs.
8. C.L.	34 M	0.25	10 Hrs.	Abdominal pain & drowsiness	-do-	Absconded after 8 hrs.
9. S.S.	50 M	0.25	6 Hrs.	Blindness & Shock	-do-	Recovered
10. K.	60 M	0.25	12 Hrs.	Blindness	-do-	Partial recovery from blindness
11. K.S.	50 M	0.25	12 Hrs.	Blindness	-do-	Vision recovery after 6 days
12. R.K.	40 M	0.25	72 Hrs.	Blindness; Vertigo	Absent	Vision recovery after 4 days
13. A.D.	24 M	0.25	14 Hrs.	Shock, blindness	Present	Recovered in 8 days
14. M.S.	22 M	0.25	14 Hrs.	Shock, Abd. Pain	Present	Recovered in 5 days

TABLE 2.—Analysis of Electrocardiograms: 11 Cases of Methanol Poisoning

Case	P WAVE					P-R Inter- val (Sec.)	QRS Dura- tion (Sec.)	QRS Frontal Plane	Ampli- tude RV ₁ m.v.	QT- inter- val (Sec.)	Transi- tional zone	Others
	Heart rate	High Milli- volts	Shape	Dura- tion (Sec.)	Frontal Plane axis							
4*	154	4.5	Peaked	.08	+86°	.14	.06	+113°	13	.24	V-5	—
5*	138	4.0	Peaked	.07	+83°	.10	.08	+76°	9	.26	V-5	—
6*	148	3.5	Peaked	.08	+72°	.12	.07	+82°	8	.25	V-4	—
7*	143	3.5	Peaked	.9	+72°	.10	.06	+96°	7	.28	V-5	—
8@	108	3.0	Peaked	.08	+83°	.10	.08	+46°	3	.32	V-4	—
9 First	104	4.0	Peaked	.08	+82°	.10	.12	+122°	17	.32	Not upto V-6 Com- plete RBBB.	—
After reversal (72 hrs.)	100	2.0	Less Peaked	.08	+75°	.12	.12	+110°	17	.34	V-6 Did not revert	—
10 First	90	3.0	Peaked	.09	+78°	.12	.08	+58°	2	.32	V-5	—
After reversal (44 hrs.)	82	2.0	Flat	.10	+33°	.14	.08	+64°	2	.30	V-4	—
11 First	110	3.5	Peaked	.08	+86°	.10	.07	+86°	8	.30	V-5	—
After reversal (48 hrs.)	94	2.5	Flat	.08	+73°	.11	.08	+42°	4	.32	V-4	—
12	98	2.5	Peaked	.07	+68°	.10	.08	+32°	1	.38	V-3	—
13 First	94	4.0	Peaked	.08	+87°	.10	.08	+82°	9	.30	V-5	—
After reversal (24 hrs.)	98	2.0	Slurred	.07	+72°	.10	.06	+80°	5	.32	V-3	—
14 First	166	4.0	Peaked	.08	+78°	.11	.07	+81°	9	.24	V-3	—
(After 38 hrs.)	94	1.0	Normal	.10	+75°	.12	.08	+74°	7	.28	V-3	—

* Case 4, 5, 6, 7 died within 4 hours and second ECG was not taken.

@ Case 8 absconded. No second ECG could be taken.

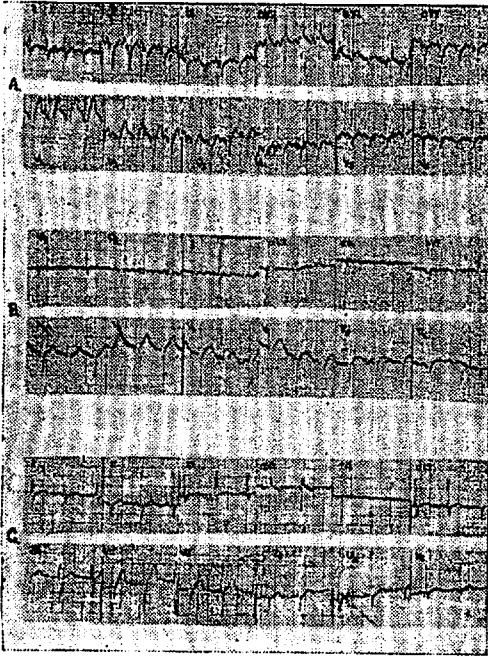


Fig. 1. Serial Electrocardiogram Case 9. Initial cardiogram (a) shows right atrial strain, Peaked P—4 m.v. high and clockwise rotation and complete R.B.B.B. Subsequent electrocardiograms B and C at 48 and 72 hours respectively show decrease in amplitude of P wave but R.B.B.B. persists.

wave in V_1 , while in others P amplitude and RV_1 amplitude normalized together. The clockwise rotation decreased in all cases. Clinically, of the 10 cases with observed E.C.G. changes, 6 were in shock. No case showed evidence of right ventricular failure in the form of engorged tender liver or dependent oedema. The pulmonary second sound was loud in all 10 cases. No murmurs were heard in pulmonary or any other areas. There was no previous history of cardiac disease in any of the cases. The case in whom complete Right Bundle Branch Block persisted, was an elderly subject, 50 years old. However no E.C.G. had ever been taken prior to poisoning episode.

COMMENTS

All our cases of methyl alcohol poisoning showed pattern of right ventricular strain as evidenced by right atrial over-

load, tall 'R' wave in V_1 , clockwise rotation and in some cases Right axis deviation electrocardiographically and a loud pulmonary second sound clinically. These changes were not related to the occurrence of shock, as they were observed in 8 cases who were without any cardiovascular symptomatology and presented with blindness alone. The regression of these E.C.G. changes along with clinical improvement suggests that they were specifically caused by poisoning. Although one of these 10 cases had evidence of chronic bronchitis with emphysema, no explanation was available for the occurrence of right side heart strain in the remaining 9 cases other than the poisoning itself.

The 'P' wave changes observed are perhaps due to pulmonary arterial Fig. 3. Serial Electrocardiogram Case 14. Ini-


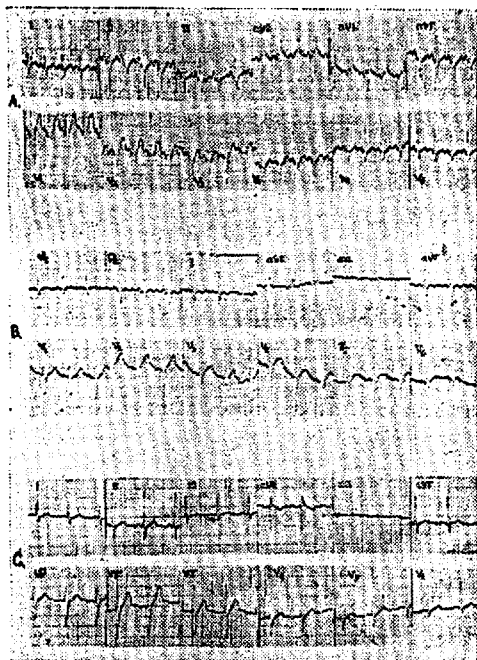


Fig. 2. Serial Electrocardiogram Case 13. Initial electrocardiogram shows P pulmonale and marked clockwise rotation. Subsequent cardiograms B and C at 12 and 24 hours show normalisation of P wave and the transition zone is now in V_3 . Complexes in V_6 are left ventricular indicating decrease in clockwise rotation.



tial electrocardiogram (a) shows marked tachycardia, right atrial strain. Subsequent electrocardiograms B & C 24 & 38 hours normalisation of heart rate and decrease in P amplitude from 4 m.v. to 2 m.v.

hypertension. The changes do not suggest an ectopic atrial rhythm. Methyl alcohol produces its toxic effect by virtue of its extremely toxic oxidative metabolites viz. formaldehyde and formic acid. Methyl alcohol poisoning has been known to produce hyperaemic and oedematous pulmonary changes on autopsy.¹

However, no data are available in literature regarding the E.C.G. during life.

The acidosis caused by methyl alcohol poisoning causes at first a rapid shallow respiration, but later respiratory failure occurs which is responsible for death in 25-50% of those cases in which the P-CO₂ is less than 20 m. eq./lit.² Hypoxia will occur during respiratory failure; and hypoxia is a known stimulus for pulmonary

hypertension as in high altitude pulmonary hypertension. Sympathetic stimulation is also known to cause pulmonary artery spasm.³ Sympathetic stimulation may be presumed to exist in states of shock or when blindness has been induced by methyl alcohol poisoning. Catecholamines are liberated during various other forms of emotional stress and physical shock, but these have not been reported to be associated with right atrial overload. In cases who presented with blindness alone, hypoxia was not clinically present and it is, therefore, difficult to incriminate hypoxia for the pulmonary hypertension and right ventricular strain. It would appear, therefore, not unreasonable to suggest that methyl alcohol has a specific deleterious effect on right heart by inducing right ventricular strain. The heart has been reported to show parenchymatous degeneration in methanol poisoning.¹ In the absence of precise haemodynamic data on the effects of methanol, it is impossible to speculate further the mechanism by which the right heart strain results.

The regularity with which the P wave changes were observed in our cases suggest that these may prove useful in the diagnosis of methanol poisoning.

REFERENCES

1. Robert, H. Dreisbach: Hand Book of Poisonings Diagnosis and Treatment, 4th Ed. p. 124. Lange Medical Publications, California, 1963.
2. Gonzales, T. A., Vance, M., Heipern, M. and Umberger, C. J.: 'Legal Medicine—Pathology & Toxicology' 2nd Ed. p. 782. Appleton-Century Crofts Inc., New York, 1960.
3. Juhani Heikkila and Kimmo-luomanmaki: Value of serial P wave changes indicating left heart failure in myocardial infarction. Brit. Heart Jr., 32(4): 510, 1970.

404) Hazra DK, Seth HC, Mathur KS, Wahal PK, Prakash V, Maheshwari BB, Tandon S.

Electrocardiographic Changes in Acute Methanol Poisoning.

J Ass Phycns India. 1974;22:409-413.

METHANOL /HEART

methyl alcohol has a specific deleterious effect on the right heart, inducing an electrocardiographic pattern of right ventricular strain. This was evidenced by right atrial overload, clockwise rotation and in some cases, right axis deviation.

Sir:

I have an interest in the chronic toxicity of methanol in Humans.

Aspartame is now the major source of methanol in the diet with the ability to increase the average intake of this toxin well above the baseline of normal methanol exposure.

I hope that these articles may help you understand the basis of symptoms your patient may be experiencing from consumption of this controversial food additive.

Woodrow C. Monte Ph.D.

Professor of Food Science (retired)

Arizona

HAZRA, D. K., H. C. SETH, K. s. MATHUR, P.K. WAHP.K. WAHAL, V.PRAKASH, B. B.MAHESHWARI and S.TANDON: Electrocardiographic changes in acute methanol poison- J. Ass. Phycns. India 22 (1974) 409-413.

WEISBERGER,A.S, and J.A.MACLAUGHLIN: Electrocardiographic changes associated with methyl alcohol poisoning. Amer. Heart J. 33 (1947) 27-33.

ELECTROCARDIOGRAPHIC CHANGES ASSOCIATED WITH METHYL ALCOHOL POISONING

LIEUTENANT AUSTIN S. WEISBERGER AND LIEUTENANT JAMES A. MACLAUGHLIN
MEDICAL CORPS, UNITED STATES NAVAL RESERVE

THE toxicity, pathologic findings, and treatment of methyl alcohol poisoning are well known and have been reviewed by Voegtlin and Watts,¹ Jacobson, Russell, Grimm, and Fox² and Kaplan and Leverault.³ Electrocardiographic changes, however, are not mentioned in these reviews, and a survey of the literature reveals only one case report⁴ in which electrocardiographic changes were demonstrated. Furthermore, no mention of electrocardiographic abnormalities associated with wood alcohol poisoning is made in standard medical textbooks. The following report deals with eight cases of methyl alcohol poisoning in which electrocardiographic studies were undertaken.

CASE MATERIAL

Nine men accidentally ingested various quantities of methyl alcohol from an unmarked container under the assumption that it was grain alcohol. The alcohol was diluted approximately one part in three with water, and the amounts ingested varied from five to six large cupfuls to a few sips. The exact amounts ingested could not be ascertained accurately. All were admitted to the hospital two days later. One man died about forty-eight hours after drinking this mixture and one became blind. The others recovered entirely.

Headache, nausea, vomiting, blurring of vision, scotomas, weakness, myalgia, and lassitude were common complaints in all and existed in varying degrees of severity. Of the eight patients who survived, two appeared seriously ill on admission, one of the men being semicomatose. Two of the patients appeared mildly ill and the remainder had only minor complaints. Hyperpnea and râles in the lung bases were noted in three of the men and cyanosis in two. Otherwise the physical findings were not striking. Six patients had a positive test for acetone in the urine.

Treatment consisted of parenteral fluids, sodium bicarbonate by mouth, Ringer-lactate solution intravenously, and liver extract intramuscularly. Four of the patients received small doses of insulin with large amounts of glucose. The most seriously ill patients received plasma.

Electrocardiograms were taken twelve hours after admission, five days after treatment had been instituted, and again eleven days after admission.

RESULTS

Seven of the eight cases showed definite electrocardiographic changes which reverted toward normal following treatment (Table I). Five showed marked abnormalities and two showed changes of lesser degree. One man had a normal electrocardiogram except for slight prolongation of the Q-T interval. Electro-

* 1740

WEISBERGER

TABLE I. ELECTROCARDIOGRAPHIC FINDINGS AFTER INGESTION OF METHANOL.

CASE	RELATIVE ESTIMATED AMOUNTS OF METHANOL INGESTED	CLINICAL APPEARANCE	ECG TWELVE HOURS AFTER ADMISSION	ECG FIVE DAYS AFTER TREATMENT	ECG ELEVEN DAYS AFTER TREATMENT
1	++++	Seriously ill	Low voltage T in Leads I and II; T ₃ is electric	Increased voltage of T in Leads I, II, and III	No change from previous tracing
2	±	Appeared normal	Normal except for slight prolongation of Q-T interval	No change	No change from previous tracing
3	++++	Appeared normal	Low voltage T in Leads I, II, and III; T in CF ₁ diphasic	Increased voltage of T in Leads I, II, and III; T in CF ₁ no longer diphasic	Further increase in voltage of T in Leads I and III
4	++++	Appeared normal	Low voltage T in Leads I and II; T ₃ diphasic	T ₁ increased in voltage	T ₂ increased in voltage
5	++	Appeared normal	Low voltage T in Leads I, II, III, and CF ₁	Increased voltage T in Leads I, II, and CF ₁ ; amplitude of T ₃ decreased and QRS notched in CF ₁	Further increase in voltage of T ₂ and T ₃ ; QRS no longer notched in CF ₁
6	++++	Mildly ill	Record within normal limits; T ₃ inverted	T ₂ slightly increased in voltage; T ₃ upright	Increased voltage of T ₃
7	+++	Mildly ill	Low voltage T ₁ and T ₂	T ₂ increased in voltage	Increased voltage of T ₁ and T ₂
8*	++++	Seriously ill	Low voltage T ₁ and T ₂	Increased voltage of T ₁ and T ₂ ; T ₃ now inverted	Further increase in voltage of T ₁ and T ₂

*Developed anisotropia.

cardiograms taken eleven days after admission showed continuing changes in the same direction in six of the patients.

The most frequent finding was low voltage of the T waves in Leads I and II which reverted toward normal after treatment (Figs. 1 and 2). Increased voltage of the T waves in Lead III and in CF₁ following treatment were noted in several of the patients (Table I). Minor changes in the QRS complex also occurred.

The Q-T interval as determined by the formula $K = \frac{QT^*}{\sqrt{RR}}$ was found to be slightly prolonged in four patients (Table II).

TABLE II. DURATION OF Q-T INTERVALS

CASE	BEFORE TREATMENT (SEC.)	FIVE DAYS AFTER TREATMENT (SEC.)	ELEVEN DAYS AFTER TREATMENT (SEC.)
1	.39	.39	.41
2	.40	.39	.40
3	.38	.38	.40
4	.39	.395	.39
5	.36	.37	.38
6	.37	.38	.38
7	.40	.40	.395
8	.36	.36	.36

COMMENT

The electrocardiographic changes which occurred in these patients are comparable to those found in the patient reported on by Merritt and Brown.⁴ In their patient, however, a normal electrocardiogram was found on admission and changes did not occur until four days after the ingestion of the poison and twenty-four hours after treatment had been instituted. The findings in our patients were present about sixty hours after the men had partaken of the methyl alcohol.

Somewhat similar changes, including prolongation of the Q-T interval, were found by Bellet and Dyer⁵ in seventeen patients with diabetic acidosis. However, here too, the electrocardiographic changes did not occur until twenty-four hours after treatment had been instituted. S-T segment depression also occurred in their patients but was not present in ours. Both Merritt and Brown⁴ and Bellet and Dyer⁵ attribute the electrocardiographic changes to delayed myocardial damage occurring as the result of acidosis.

The oxidation of methyl alcohol results in an acidosis due to the formation of formic acid and formaldehyde. Unfortunately, determinations of the carbon dioxide combining power were not available in these patients, but it is safe to

*Bazetts' formula corrected for Q-T interval. K is a constant. R-R is the cycle length.

5/11/46

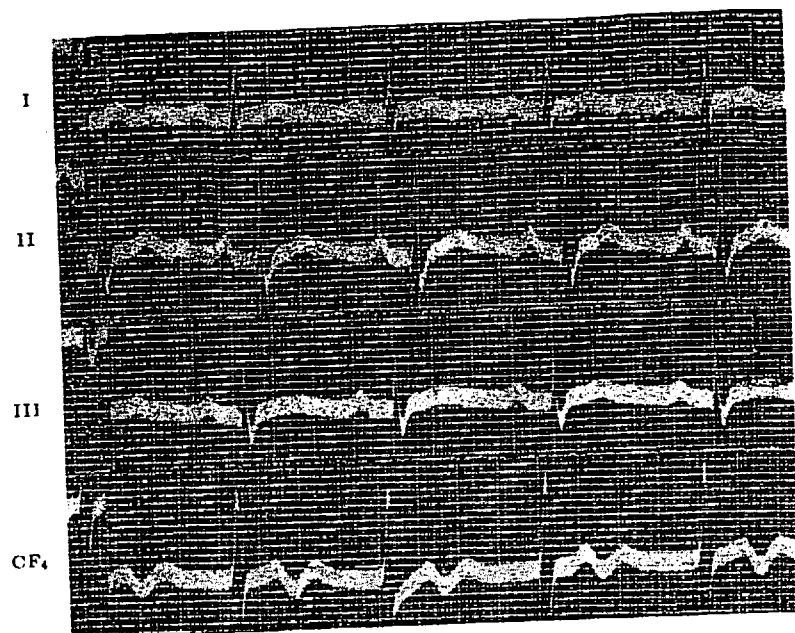


Fig. 1A.—Case 3. Electrocardiogram twelve hours after admission. Low voltage of T waves in Leads I, II, and III. T in CF_4 is slightly diphasic. Prominent U waves are present in CF_4 .

5/16/46

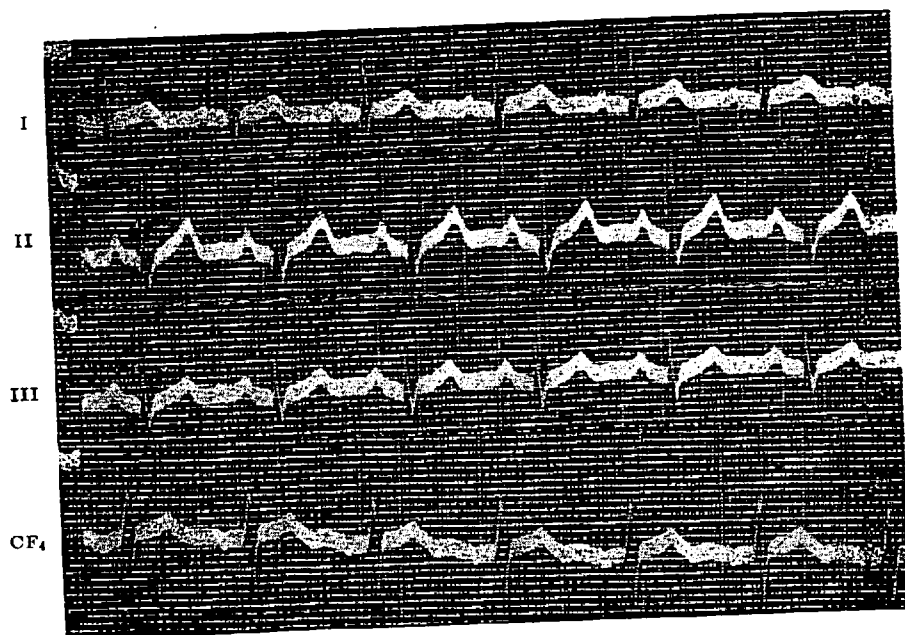


Fig. 1B.—Case 3. Electrocardiogram after treatment. T waves in Leads I, II, and III have increased in amplitude. T in CF_4 no longer diphasic.

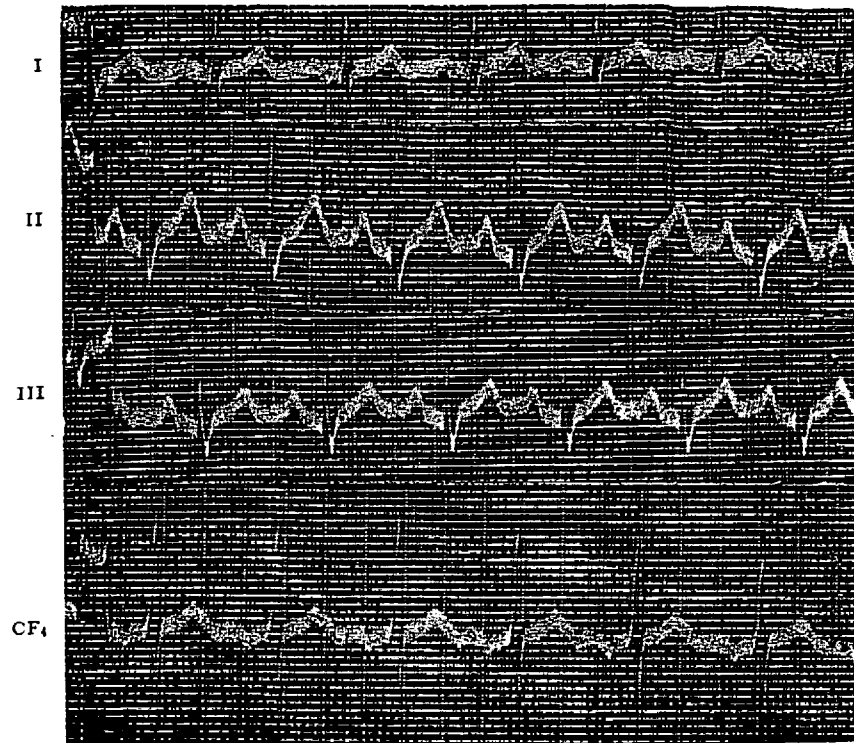


Fig. 1C.—Case 3. Electrocardiogram eleven days after treatment shows further increase in voltage of T waves in Leads II and III.

5/11/46

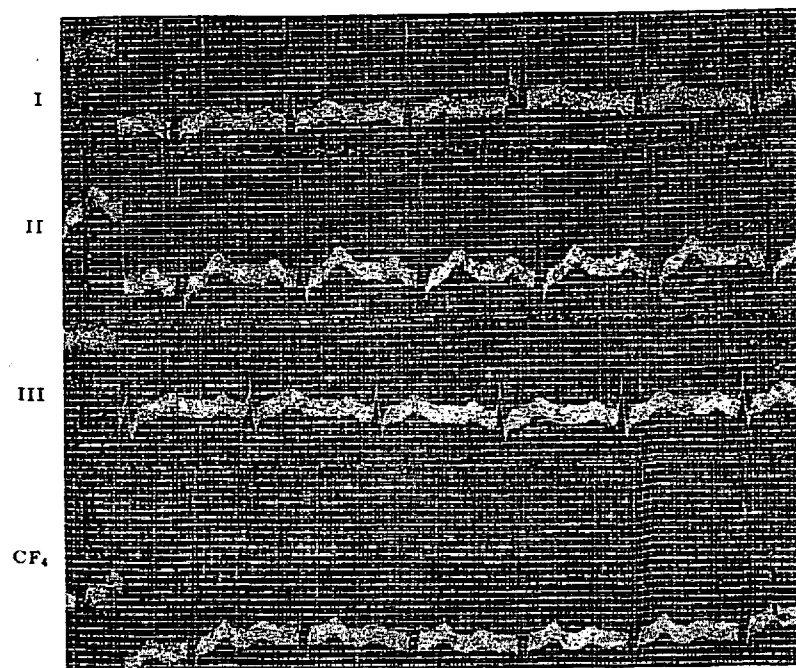


Fig. 2A.—Case 5. Electrocardiogram twelve hours after admission. Low voltage of T waves in Leads I, II, and III, and in CF_4 .

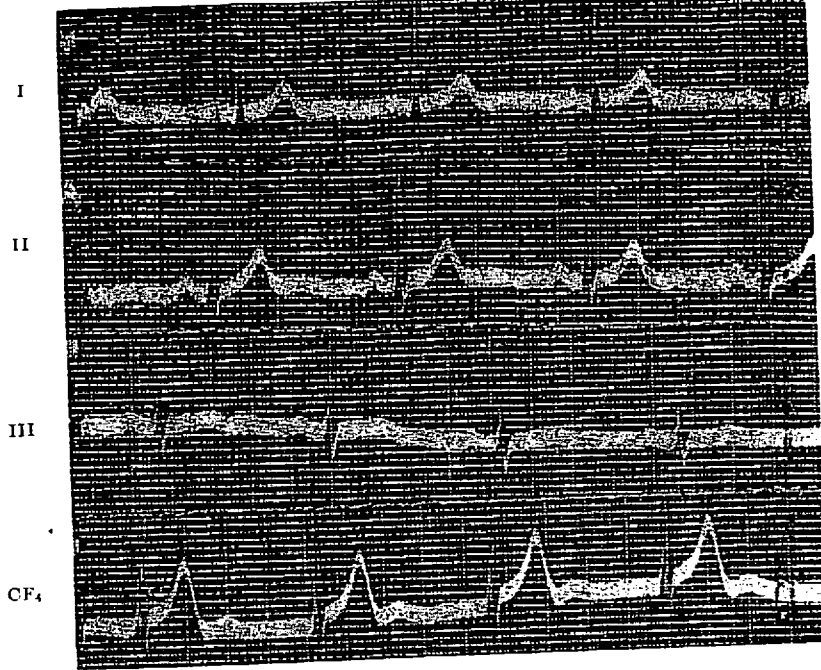
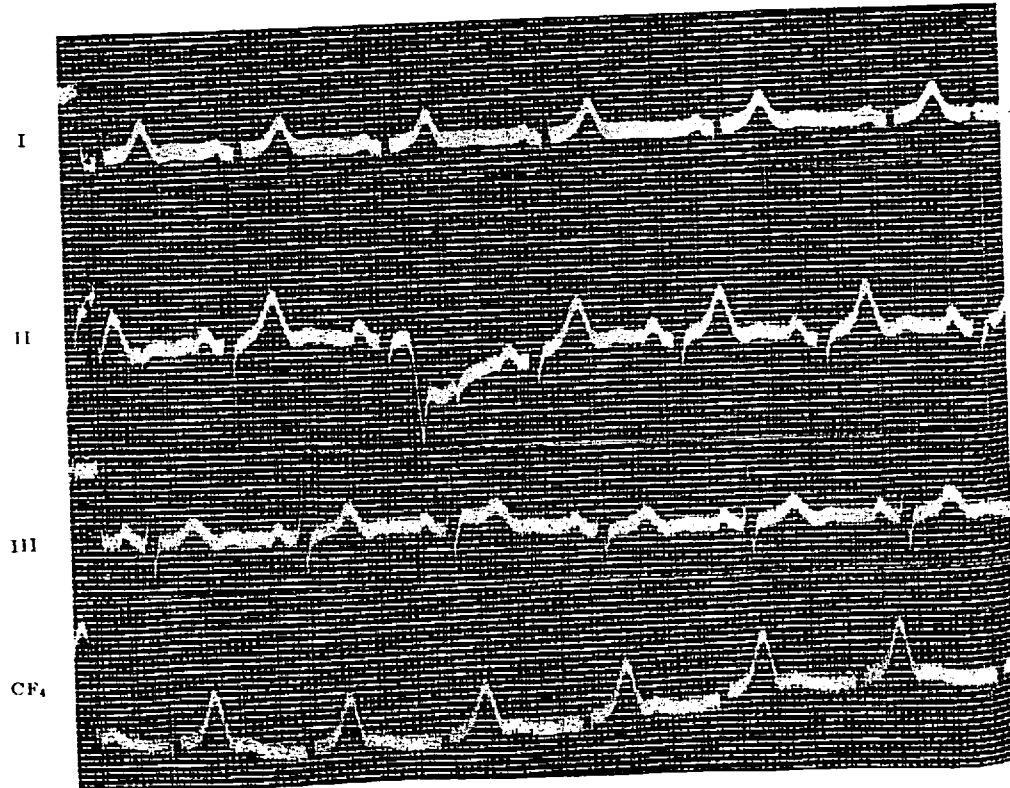


Fig. 2B.—Case 5. Electrocardiogram after treatment. Increased voltage of T waves in Leads I and II, and in CF₄. T_S decreased in voltage and QRS notched in CF₄.

5/22/46



assume that they were probably suffering from acidosis at the time of admission. However, methyl alcohol, formic acid, and formaldehyde are all toxic substances, per se, and the possibility of direct myocardial toxicity cannot be ruled out entirely.

No direct correlation could be drawn between the degree of electrocardiographic change and the estimated amount of methanol ingested. The patient (Case 2), however, who showed no change except slight prolongation of the Q-T interval, took the least amount of alcohol. It was the clinical impression that habituation to alcohol exerted a protective influence.

The Q-T intervals were found to be only slightly prolonged and were not significantly altered following treatment. No correlation could be drawn between the amount of electrocardiographic changes which occurred and the duration of the Q-T interval.

SUMMARY AND CONCLUSIONS

1. Electrocardiographic changes were found in seven of eight patients with methyl alcohol poisoning.
2. The most common finding was decrease in voltage of the T waves in Leads I and II.
3. Slight prolongation of the Q-T interval was present in four patients but did not appear to be significant.
4. The electrocardiograms reverted toward normal after treatment.
5. The cause of the electrocardiographic changes is not known but may be due to acidosis or to the direct effect of methyl alcohol or its metabolites on the myocardium.

REFERENCES

1. Voegtlin, Walter L., and Watts, Charles E.: Methyl Alcohol Poisoning, U. S. Nav. M. Bull. 41: 1715, 1943.
2. Jacobson, Bernard M., Russell, Hollis K., Grimm, Joseph J., and Fox, Everett C.: Acute Methyl Alcohol Poisoning, U. S. Nav. M. Bull. 44: 1099, 1945.
3. Kaplan, Abraham, and Leverault, Gerald V.: Methyl Alcohol Poisoning, U. S. Nav. M. Bull. 44: 1107, 1945.
4. Merritt, W. A., and Brown, A. E.: Methyl Alcohol Poisoning—Report of a Case, Proc. Staff Meet., Mayo Clin. 16: 666, 1941.
5. Bellet, Samuel, and Dyer, W. W.: Electrocardiogram During and After Emergence from Diabetic Coma, AM. HEART J. 13: 72, 1937.