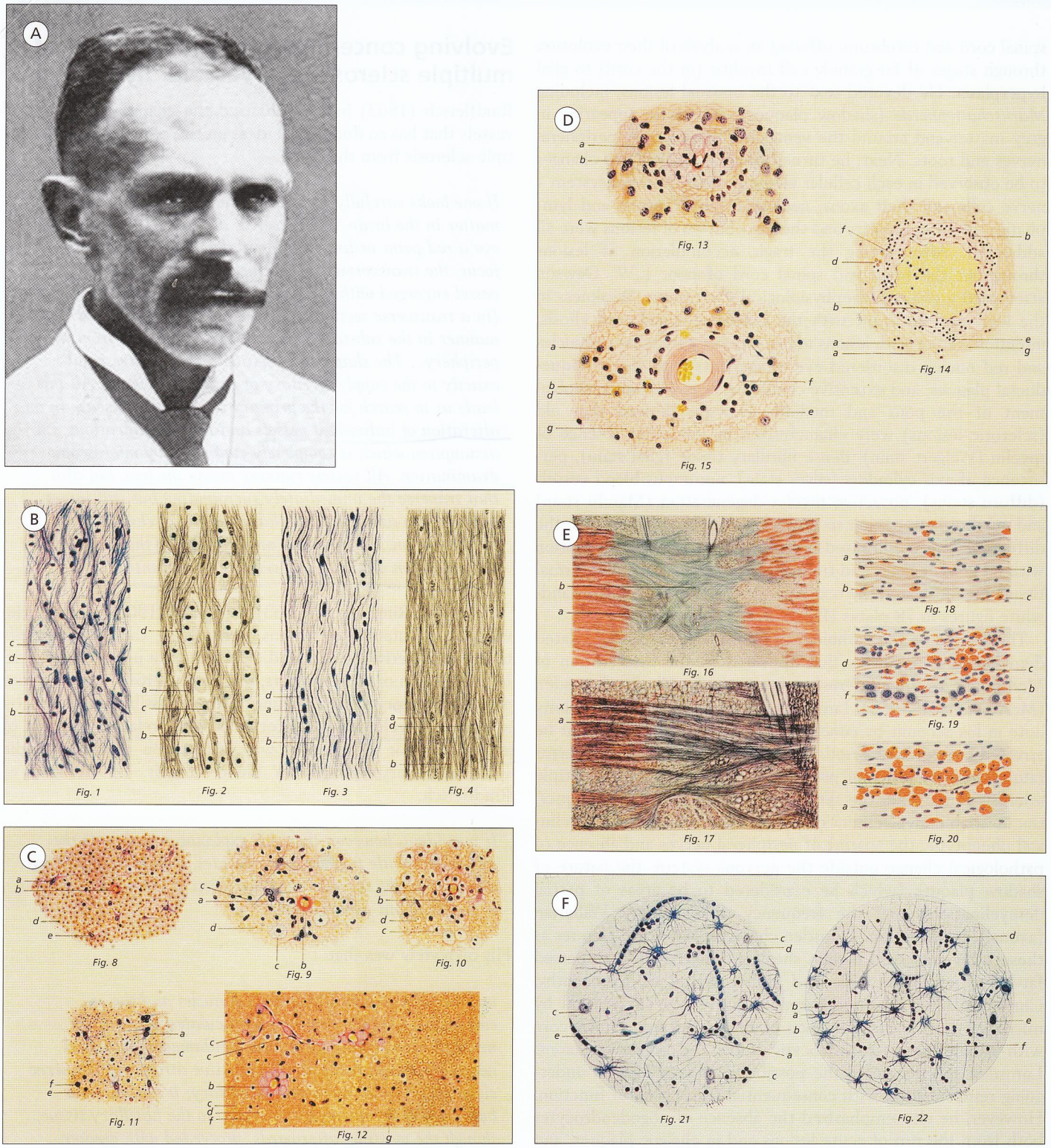

Figure 1.17 (A) James Dawson (1870–1927). (B) *Figs 1–4*: Successive stages in the evolution of a sclerotic area in the posterior columns of the cervical spinal cord. Sections cut in longitudinal direction of the nerve fibres show increasing glia fibril formation. *a*: Glia nuclei; *b*: glia fibrils; *c*: fat granule cells; *d*: persistent axis cylinders. *Figs 1 and 3*: Ford-Robertson's methyl violet stain; *Figs 2 and 4*: palladium methyl violet. (C) *Figs 8–12*: Successive stages in the evolution of a sclerotic area in the posterior columns of the cervical cord. *a*: Glia nuclei; *b*: blood vessel; *c*: fat granule cell; *d*: myelinated nerve fibre; *e*: finely granular glia tissue; *f*: naked axis cylinder; *g*: transition to normal tissue. (D) *Figs 13–15*: Sequence of changes in the blood vessels. *a*: glia nuclei; *b*: blood vessel; *c*: fat granule cell; *d*: cell containing blood pigment; *e*: lymphocyte-like cells; *f*: plasma cells; *g*: glia tissue; *h*: connective tissue cell. (E) *Figs 16 and 17*: Persistence of axis cylinders across a demyelinated area in the pons. *a*: line of transition between myelinated and demyelinated fibres; *b*: median raphe where axis cylinders intersect. *Figs 18–20*: Stages in the demyelination of an area and in the evolution of the fat granule cell. *a*: Small glial nuclei; *b*: transition forms between *a* and *b*; *c*: fat granule cell; *d*: nerve fibre; *e*: blood vessel; *f*: proliferated glia nuclei. (F) *Figs 21 and 22*: Glia changes in a completely demyelinated area in the cortex. *a*: Proliferated glia cells with protoplasm and processes differentiated into fibrils; *b*: capillaries with glia fibrils attached to their outer membrane; *c*: ganglion cells; *d*: small glia cells forming nests around the remains of ganglion cells; *e*: degenerated ganglion cells; *f*: retained axis cylinders. Note that the normal cytoarchitecture of the tissue is preserved. From Dawson (1916).

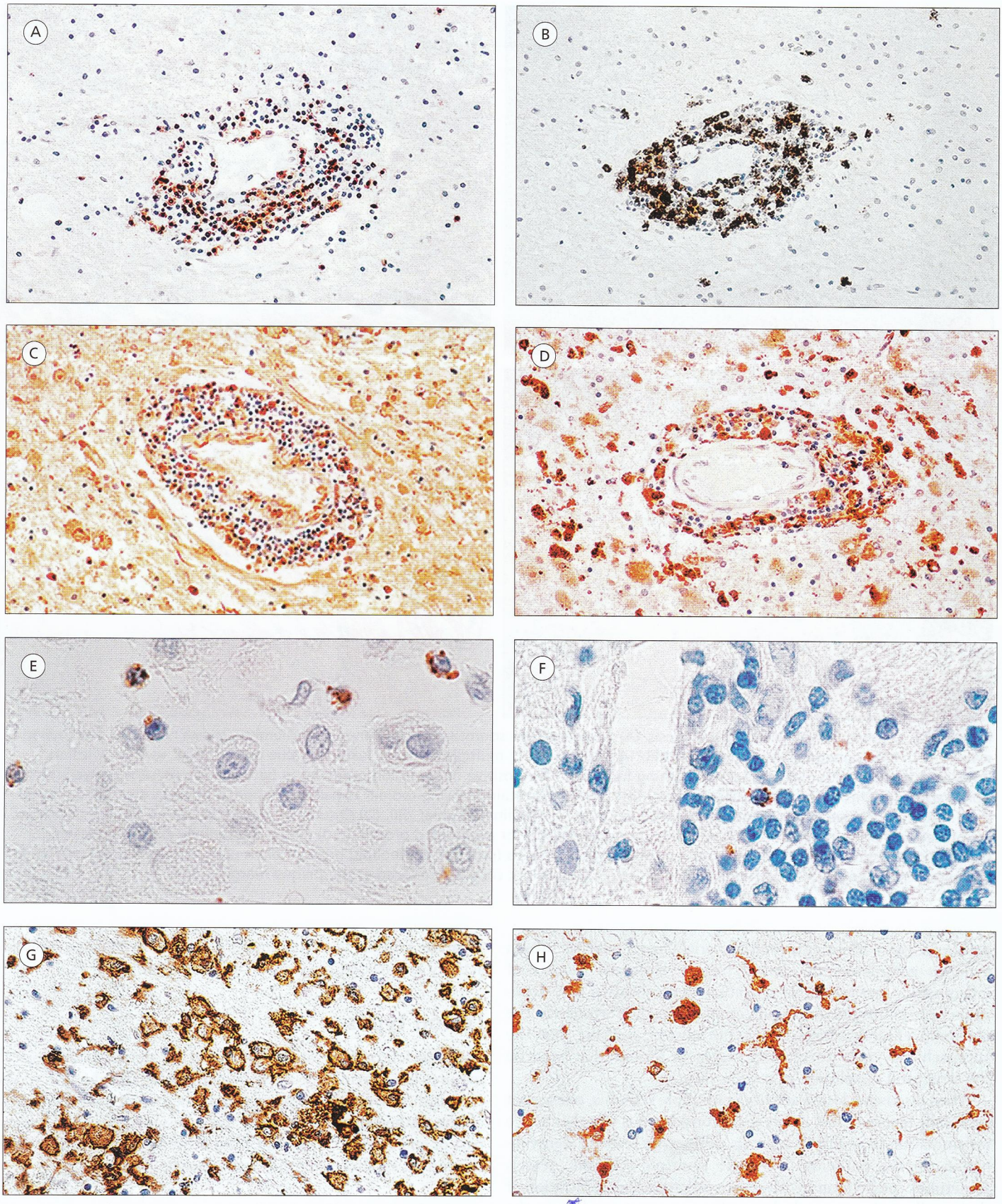

Figure 12.3 Inflammation in multiple sclerosis lesions. Acute multiple sclerosis. (A) Perivascular inflammatory infiltrates with $CD3^+$ T cells. (B) $CD8^+$ T cells. (C) IgG-containing plasma cells. (D) $CD68^+$ macrophages; ×100. (E) Acute multiple sclerosis with granzyme B-reactive cytotoxic T cells in the lesion parenchyma. (F) A perivascular cuff; ×600. (G) Primary progressive multiple sclerosis lesion with $CD68^+$ macrophages in an active plaque. (H) $CD68^+$ microglia in the normal-appearing white matter; ×300.