

Notice: This material may be protected
by copyright law (Title 17, U.S. Code)

THE BRITISH JOURNAL

OF

OPHTHALMOLOGY

DECEMBER, 1943

COMMUNICATIONS

A STUDY OF THE HISTOPATHOLOGICAL CHANGES IN THE RETINA AND LATE CHANGES IN THE VISUAL FIELD IN ACUTE METHYL ALCOHOL POISONING

BY

IAN STEWART MCGREGOR

FROM THE TENNENT INSTITUTE OF OPHTHALMOLOGY,
WESTERN INFIRMARY, GLASGOW

Introduction

In April, 1942, eighteen cases of poisoning by imbibition of methanol or methyl alcohol were treated in the Glasgow Western Infirmary.

Seven of those were gravely ill and died in hospital. We were able to secure the eyes of four of them, three men and one woman, for histological examination. In our investigation of the literature we were struck by the few histological examinations that have been made of the retinæ of the victims of this poison. It is not common in this country, to have outbreaks of acute illness resulting in death from drinking methanol. Its use as an adjuvant, or fortification, to other drinks, is frequent on the Continent and was common in the days of prohibition in America. This may lead to gradual deterioration in vision. Similarly, it has been described

as occurring in industries, such as varnish and shellac manufacture, where the fumes are absorbed from the lung. It may also be absorbed from the skin.

Throughout the literature the same difficulty is encountered, namely, how much spirit did the patient have? The amount necessarily lethal is variable. Our fatal cases probably had several ounces of spirit over the forty-eight hours before admission to hospital. As nearly as we could estimate, one of the men who recovered and whose field of vision we discuss later, probably had six ounces at least, diluted in beer and coffee.

Wood-spirit drinking in sporadic cases may often be ignored as a cause of death. Jackson believes it to be one of the commonest causes of toxic blindness in America. But the incidence of several cases with a similar clinical picture from whom a history of a recent drinking bout can be obtained, should make one suspicious. Especially is this so if the potion has been retailed from one source mainly. It was sold clandestinely to our patients as gin, at a shilling a bottle, in a public house in the town. Where the history of drinking is not obtained, the picture may be puzzling. A practitioner who was called to see the husband and wife who died and whose retinæ we report on, found them stuporose and cyanotic. He told us he could not make up his mind what was the matter before he sent them to hospital.

It might be well here to sketch the clinical picture presented by those people on admission to hospital. The gravely ill were comatose, pale or cyanotic, perspiring and profoundly shocked. The pupils were widely dilated and immobile. As death approached cyanosis increased and the pulse became less and less perceptible. The four cases which came to post-mortem were in this category; one lived only two hours after admission. Sometimes convulsions preceded death. In the less severe type, the patient was confused, perspiring, pale, with the cramps and abdominal pains of acute irritant poisoning. Vision deteriorated in one case to the perception of hand movements within twelve hours of admission. This man, whose field of vision we shall later discuss, recovered useful vision. A common symptom is yellow vision. The patient may be comatose and recover, and he may be blind and recover vision, at least in large part. The milder cases have gastro-intestinal symptoms with transient dimness of vision.

Ophthalmoscopic signs are usually present in severe cases. Indistinctness of the disc edges and congestion of the veins suggested oedema of the nerve head. Oedema of the retina around the disc was apparent in some. One man who was admitted in

coma recovered rapidly and right and left, on recovery necessarily accompany a produce coma.

The principles of treatment were elimination by maintenance of diuresis by intravenous glucose and respiratory stimulants. It is slow (Haggard and Green).

Our interest in the incident is a scrutiny of the literature regarding the histology of the retina in the human. These findings on examination of the literature changes in the nucleus of change in the nerve. We used a technique by examining the change in addition to the retina those of the surviving patients their visual impairment, if any, thought that a study of the appearances would be useful. of wood spirit in producing blindness.

Histology

It is our custom where possible to inject 10 per cent. formal-saline into the vitreous. In the four cases to be discussed the layer is never so intact in the haemalum and eosin section. The retina for routine paraffin embedding was stained for routine paraffin embedding, the whole remaining on a slide. This was examined in bulk with Speilmeyer's scarlet. After examination in bulk portions were in gelatin and sectioned.

The nerve was examined by degeneration, the rapid method of Smith and Quigley was used. Sections of the nerve were examined with eosin. Having in mind the pitfall of a normal nerve subjected on it from the skull and another portion by subjecting it to a weight of 1

EGOR

nish and shellac manu-
the lung. It may also

difficulty is encountered,
ent have? The amount
uses probably had several
urs before admission to
te, one of the men who
discuss later, probably
ed coffee.

is may often be ignored
s it to be one of the
America. But the in-
inical picture from whom
be obtained, should make
if the potion has been
as sold clandestinely to
tle, in a public house in
ing is not obtained, the
er who was called to see
ose retinae we report on,
le told us he could not
before he sent them to

nical picture presented by
l. The gravely ill were
and profoundly shocked.
d immobile. As death
ulse became less and less
e to post-mortem were in
after admission. Some-
the less severe type, the
, with the cramps and
ing. Vision deteriorated
movements within twelve
field of vision we shall

A common symptom is
matose and recover, and
least in large part. The
atoms with transient dim-

present in severe cases.
gestion of the veins sug-
tema of the retina around
nan who was admitted in

coma recovered rapidly and his visual acuity was 6/9 Snellen,
right and left, on recovery so that gross visual loss does not
necessarily accompany a degree of poisoning sufficient to
produce coma.

The principles of treatment employed in the medical wards
were elimination by maintained gastric lavage and the promotion
of diuresis by intravenous glucose salines, lumbar puncture, cardiac
and respiratory stimulants. The elimination of methyl alcohol
is slow (Haggard and Greenberg).

Our interest in the incident of this outbreak was aroused because
a scrutiny of the literature revealed only four papers that we could
find on the histology of the retina and nerve in methanol poisoning
in the human. These findings, as we shall show now from an
examination of the literature, were the changes of oedema with
changes in the nucleus of the ganglion cells, and little if any
change in the nerve. We sought to use additional variations of
technique by examining the retina in bulk, staining for lipoid
change in addition to the routine methods. Then we examined
those of the surviving patients who would submit, to estimate
their visual impairment, if any. Now that a year has elapsed we
thought that a study of the visual fields and ophthalmoscopic
appearances would be useful. The problem of the mode of action
of wood spirit in producing blindness is unsettled.

Histological Methods

It is our custom where possible to inject a few minims of 8 per
cent. formol-saline into the vitreous as soon after death as possible.
In the four cases to be discussed this was not done. The fibre
layer is never so intact in such circumstances in the routine
haemalum and eosin sections. After trephining a portion of
retina for routine paraffin embedding and haemalum and eosin
staining the whole remaining retina was removed and spread flat
on a slide. This was examined by the method of staining in
bulk with Speilmeyer's scarlet red for fat and mounted in glycerin.
After examination in bulk portions were removed and embedded
in gelatin and sectioned.

The nerve was examined by Marchi's impregnation for myelin
degeneration, the rapid method of staining myelin described by
Smith and Quigley was used instead of Weigert-Pal. Serial
sections of the nerve were examined by routine haematoxylin and
eosin. Having in mind the pitfalls of Marchi's method we stained
a normal nerve subjected only to the trauma of removing
it from the skull and another portion which was traumatised further
by subjecting it to a weight of 14 lbs. for 24 hours.

Literature

As we have stated, the communications dealing with the pathological changes in the retina in methanol poisoning are few. The work of Pick and Bielschowsky, McDonald and Menne are quoted in the text of the next section under "Histological Findings in the Retina." We have been unable to procure the paper of the Russian, Eleonskaja.

The literature shows two peaks of interest. On the Continent there was an outbreak of acute poisoning in 1911 in Berlin. In America during the years of prohibition there was a great increase in the number of addicts to denatured or "dehorn" alcohol.

The Berlin outbreak resulted from the drinking of cheap schnapps. There were 130 cases, and 58 died. The severe cases had marked gastro-intestinal symptoms with respiratory distress and cyanosis later. Onset of symptoms was 24-36 hours after drinking. The pupil was maximally dilated, not responding to light or accommodation. The vision failed and blindness was common. There was no paralysis of the extra-ocular muscles. Death was attributed to paralysis of the respiratory centre. Mild cases exhibited loss of vision with moderately dilated but reacting pupils and sickness. Thirty of the cases were sick only, with no other features. In those who survived the vision tended to improve but it was impossible to give an accurate prognosis as sometimes the mild cases deteriorated in vision without any warning signs (Hirschberg).

Ophthalmoscopically where changes were noted they constituted a hyperaemia of the disc and congestion of the veins in the early stages. Of those who survived, 75 per cent. had some change in vision. They showed optic atrophy with a marked atrophic cup. It was emphasised that the large pupil was a sign that the danger of further loss of vision was not past. There is often a stage of improvement followed by deterioration. Lewy often found no change in the fundus, or at the most a slight opaqueness of the tissue of the disc. These had just as high an incidence of subsequent atrophy. On the other hand, he found that some cases of neuritis disappeared without any visual loss. Rost found that in convalescence the field was generally contracted and there was an absolute central scotoma. He believed that the diagnosis was easy, provided the condition was kept in mind. He believed that all methyl alcohol substances should be on the list of poisons. In therapy he employed gastric lavage and enemata, strychnine, caffeine and hot packs.

In America the first reports of poisoning appear as early as 1879. By the end of the century there were many reports of blindness from this cause as the spirit, which had been treated to remove

the bad taste, was put on the Congress passed the Denatured Alcohol Act of 1906. Cases of poisoning were reported about 1900. Special sensitiveness to the poison was reported to cause blindness, and 100 c.c. of a concentration of as little as 10 per cent. was known to cause poisoning.

The tendency to recover after poisoning went on to blindness. In Edinburgh, the experience was slight or absent. Other cases where the subsequent vision is always lost when the patient is at his worst.

The symptomatology is diverse. In acute cases. Headache, abdominal pains, cardiac depression, marked prostration, delirium, convulsions, stupor, and coma. The visual symptoms are loss of vision, moving the eyes, and hemeralopia. Lowered tension sometimes, dilated pupils, normal or congested discs and chronic poisoning are the central features, either complete atrophy or pallor.

The general pathological findings are a low acid content of the aqueous; but increased viscosity of the vitreous, leucocytes and haemo-concentration are decreased. There is a high concentration in consequence of the acidosis. Mucosal haemorrhages. Menne's examination of twenty-two victims in Wagonia County, Ore., who died in hospital, five were comatose and the remainder stuporose. Shocked, cold, clammy, and cyanotic.

The blood pressure of those who died was systolic 110 to 140, and diastolic 70 to 90. In some cases ill to comment on visual symptoms. Laboured spasmodic, respiration. The time of death was 2 or 3 per cent. in the late stages. Death was f

the bad taste, was put on the market. It was not until 1906 that Congress passed the Denatured Alcohol Bill. Between that time and the advent of prohibition in 1918 there were few cases reported. Cases of poisoning from inhalation and external application were reported about this time. Some people showed a special sensitiveness to the poison. In some, 10 c.c. was enough to cause blindness, and 100 c.c. had been known to cause death. A concentration of as little as 0.2 per cent. in the air had been known to cause poisoning.

The tendency to recover vision was considered poor. De Schweinitz (quoted Traquair) reckoned that 90 per cent. of cases of poisoning went on to blindness. Traquair, speaking of his experience in Edinburgh, thought that the tendency to recover was slight or absent. Other authors do not agree and state that the subsequent vision is always better than the vision existing when the patient is at his worst.

The symptomatology is divided into general and ocular manifestations in acute cases. Headache, dizziness, nausea and vomiting, abdominal pains, cardiac weakness, slow pulse, sighing respiration, marked prostration, weakness of the extremities, delirium, convulsions, stupor, and death are the general features. The visual symptoms are loss of vision, photophobia, pain on moving the eyes, and hemeralopia. The signs in the eye are lowered tension sometimes, dilated and fixed or sluggish pupils, normal or congested discs and central scotoma. The signs in chronic poisoning are the central scotoma with an atrophic nerve head, either complete atrophy or limited to the temporal side, with pallor.

The general pathological findings are acidosis with increased acid content of the aqueous; blood shows a reduced coagulation time, but increased viscosity with increase of erythrocytes and leucocytes and haemo-concentration. The lymphocytes, however, are decreased. There is a high output of ammonia in the urine in consequence of the acidosis. The gastro-intestinal tract shows mucosal haemorrhages. Menne writes of the complete pathological examination of twenty-two victims of methanol poisoning in Multnomah County, Ore., who died in 1934. He said that of the fifteen who were hospitalised, five were comatose, five were conscious, and the remainder stuporose. Most of them were profoundly shocked, cold, clammy, and perspiring excessively.

The blood pressure of those in which it was recorded was, systolic 110 to 140, and diastolic 78 to 90. Most of them were too ill to comment on visual symptoms. They all had irregular, often laboured spasmodic, respiration. The rate varied, and nearing the time of death was 2 or 3 per minute. Cyanosis was marked in the late stages. Death was from respiratory failure. Many

were pulseless on arrival in hospital; in some others the heart-rate was rapid but in most it was slowed in company with the respiration. Terminal convulsions were present in three cases. He expresses the usual doubt in assessing the amounts of alcohol taken. He could say that as much as 500 c.c. of spirit was drunk by one man. Similar difficulty is expressed in estimating the time elapsing between intake and onset of symptoms but in most it was from 16-24 hours. It was earlier in some. Six patients died within an hour of hospitalisation, three within five minutes, and the remainder within one to seven hours.

The changes found post-mortem in the central nervous system were sub-pial and moderate cortical and sub-cortical interstitial oedema. Only occasional focal haemorrhages were seen. On the whole the cellular changes were not marked. "The extensive degeneration of the ganglion cells and the vascular endothelium with subsequent haemorrhage in the mid-brain, pons and medulla oblongata referred to by Weil was not observed, probably because of the acuteness of the intoxication," Menne says. We quote him again—"Geitler and St. George noted only pronounced cerebral congestion with an increase of spinal fluid and engorgement of blood vessels."

Detailed studies of brain histology were wanting, but he quotes the experimental work of Eisenberg who examined rabbits after a period of inhalation of 0.2 per cent. wood alcohol for periods of two, four, six, eight, and ten months. Eisenberg found degeneration of various degrees with an indefinite line of demarcation between the gray and the white matter, diminution of neurocytes, with spindling and disappearance of Nissl granules, and a scattering of brownish pigment. In the later stages of the severe intoxications in these rabbits there was a marked decrease in the size and number of parenchymal cells. The nuclear changes varied in degree up to complete karyolysis. We quote Menne again—"Scott and his associates exposed monkeys, rabbits, and rats to methyl alcohol by cutaneous absorption, inhalation and ingestion. They found in their animals, capillary congestion, oedema and patchy degeneration of the neurons. These changes were more often found in the spinal cord than in the brain. These authors quote Rühle as having found in dogs scattered haemorrhages along the blood vessels of the pons, medulla and cord as well as large amounts of lipoid in the vascular endothelium and perivascular tissue. The deposition of lipoid often preceded the haemorrhage. Scott and his co-workers concluded that only parenchymal and neuronal tissues were affected. Such experimental evidence is probably of more value in depicting the injurious effect of methyl alcohol on the central nervous system than are the changes observed in such acute conditions as I have

described in human beings controlled. However, the wood alcohol must be such wide variation in. The derivation of formic the real changes in the p because of their fixative a

Menne's examination from each body with for him to state that "the million cells of the retina with placement of nuclei, fraying and autolysis. In many cells approached normal, absent from wide areas.

most marked near the di the glial cells, except oede without notable alteration was seen in the optic nerv

He found no hyperten regular addicts to wood to any other, and were habits. In only one was of a minor degree. Many no focal lesions such as are The alimentary tract shows haemorrhages and, in the neys were enlarged slight minute structure was re changes of note found in h

The remarkable fact was people who regularly cor There was nothing to show ceptibility to disease or h tion and decay. The changes regarded as selective, but ability of specialised tissues manifestations of disturbed convulsions, shows toxic e mentally Gradinesco and tions (5 per cent. to 10 per then diminution of response effect undoubtedly varies persons, hence the peculiar states. The accidental deaths of addicts was due to the ir

ne others the heart-rate
npany with the respira-
t in three cases. He
he amounts of alcohol
c.c. of spirit was drunk
ssed in estimating the
symptoms but in most
n some. Six patients
ee within five minutes,
rs.

central nervous system
sub-cortical interstitial
ges were seen. On the
ked. "The extensive
vascular endothelium
rain, pons and medulla
rved, probably because
e says. We quote him
ly pronounced cerebral
d and engorgement of

wanting, but he quotes
xamined rabbits after a
alcohol for periods of
enberg found degenera-
ine of demarcation be-
nition of neurocytes,
granules, and a scatter-
ges of the severe intoxi-
decrease in the size and
lear changes varied in
quote Menne again—
s, rabbits, and rats to
halation and ingestion.
ngestion, oedema and
ese changes were more
brain. These authors
cattered haemorrhages
lla and cord as well as
endothelium and peri-
d often preceded the
concluded that only
fected. Such experi-
alue in depicting the
entral nervous system
te conditions as I have

described in human beings, material which is not so accurately controlled. However, the susceptibility of the tissue of animals to wood alcohol must be considered in the evaluation, since there is such wide variation in the effects in different animals studied. The derivation of formic acid and the alcohol itself may becloud the real changes in the parenchyma of the central nervous system because of their fixative action."

Menne's examination of the eyes of which one was removed from each body with formalin fixative and routine staining led him to state that "the most pronounced changes were in the ganglion cells of the retina which showed irregular staining, eccentric placement of nuclei, fraying of cycloplasmic outlines, vacuolation and autolysis. In many cases only about one in fifty of these cells approached normal, while in some of the eyes they were absent from wide areas. These changes in the ganglion cells were most marked near the disc. There were no marked changes in the glial cells, except oedema. The other layers of the retina were without notable alterations, with ordinary stains." No change was seen in the optic nerve.

He found no hypertensive changes in those people who were regular addicts to wood spirit, they even preferred wood spirit to any other, and were well known in the community for their habits. In only one was there cirrhosis of the liver, and that was of a minor degree. Many livers were enlarged, but there were no focal lesions such as are seen in experimental alcohol poisoning. The alimentary tract showed congestion of the mucosa and small haemorrhages and, in the stomach, areas of necrosis. The kidneys were enlarged slightly, engorged, and greyish, but the minute structure was remarkably preserved and there were no changes of note found in heart, spleen or pancreas.

The remarkable fact was the good bodily preservation of these people who regularly consumed wood spirit in small quantities. There was nothing to show that it had produced an increased susceptibility to disease or had hastened the processes of degeneration and decay. The changes in the retina and brain were not regarded as selective, but merely the result of the greater vulnerability of specialised tissues to the poison, which in its clinical manifestations of disturbance of the respiratory centre, blindness and convulsions, shows toxic effects on the nervous system. "Experimentally Gradinesco and Degan showed that in weak concentrations (5 per cent. to 10 per cent.) methanol causes excitability and then diminution of response going on to complete paralysis. The effect undoubtedly varies with the rate of oxidation in different persons, hence the peculiar and varying clinical episode," Menne states. The accidental death of this series of cases of known addicts was due to the inadvertent sale of pure methanol. The

normal industrial strength for most purposes in America has been reduced from 10 per cent. to 2 per cent.

Ethyl alcohol disappears from the body by two processes; elimination, largely through the lungs; and oxidation in the tissues. On the other hand, methyl alcohol is also eliminated through the lungs, but it is not oxidised in the tissues to a great extent.

"The elimination of both alcohols is controlled by the same principle. It is the principle which has been described mathematically by Haggard for the elimination of ethyl ether, an entirely non-reactive substance. In the operation of this principle the co-efficient of distribution of any volatile substance between the blood and air in the lungs plays an important part. For methyl alcohol the co-efficient is high; that is, its solubility in the blood is high in relation to its vapour tension in the pulmonary air. The elimination of methyl alcohol through the lungs therefore is much slower than ethyl ether which has a lower co-efficient of distribution." (Haggard and Greenberg). "Only about 10 per cent. of the total amount of ethyl alcohol which disappears from the body is eliminated in the expired air. For methyl alcohol on the contrary, Voltz and Dietrich have estimated that approximately 30 per cent., is eliminated; and Asser has estimated 53 per cent. We find that more than 70 per cent. of the amount disappearing from the body appears in the expired air. We find further that the rate of elimination is not constant, but instead is a function of the concentrations in the blood and of the volume of the pulmonary circulation; that the curve obtained by plotting the concentrations of methyl alcohol in the blood is exponential; and that the rate of loss of methyl alcohol by elimination through channels other than the lungs and by oxidation, is not constant, but is likewise a function of the concentration in the blood." (Haggard and Greenberg).

The only addition to the usual eliminative therapy with cardiac and respiratory stimulation that we could find was the suggested efficacy of thiamine hydrochloride in a case quoted by Simons which recovered vision. He states that he is aware that recovery might have taken place without thiamine, but that its use may be worth while. According to Norbury, "The chief physiologic role of vitamin B₁ in the body is regulation of cellular respiration." Nerve cells require relatively more oxygen than other types of cells and they are more susceptible to any lack of oxygen. If Friedenberg is correct when he says that in methyl alcohol poisoning, as in beestings, it is the formic acid that causes strangulation of the optic nerve fibres by the sudden tissue swelling, then it seems reasonable that an increased amount of thiamine would be of value in combating the anoxaemia.

Traquair described the condition thus—"The clinical picture and others is that of three days after ingestion of a complete or nearly complete loss of vision, always affected though it may take even weeks, according to the degree of the defect, to return at the field periphery through at one side or the other. The breaking through may be gradual, sometimes pseudo-hemianopia, and may recover more or less completely."

The defect is pericentral, though it often involves the central vision usually high. According to the degree of size, intensity and persistence of the defect, little or no recovery may be expected. Vision may be restored by a second attack, but with pallor of the optic disc and contracted Goldflam notes that recovery had reached normal vision and return and remain when the attack begins with.

The field changes indicate damage to retinal cells and optic nerve elements. The ultimate degree of recovery is probably due to the degree of atrophy depending on the violence of the attack.

The diagnosis depends on the clinical picture which usually suggests this condition. It should be guarded at first, but greatly improved, as second attacks should therefore be watched for.

Histological

Four retinæ were available for examination. The first was first examined in bulk and then mounted in glycerin. By this method the whole retina at once and to a great extent. With high power, and with the use of the ganglion cells to examine the focusing adjustment of the focusing adjustment of the details of contour are enhanced by the dynamic microscopy technique.

Traquair described the field changes in methyl alcohol poisoning thus—"The clinical picture as described by Uhthoff, Goldflam and others is that of an acute intoxication. Usually two or three days after ingestion the visual loss commences, and complete or nearly complete blindness rapidly ensues. Both eyes are always affected though often unequally. After several days or even weeks, according to the severity of the case, vision begins to return at the field periphery, and a large absolute defect broken through at one side or the other becomes demonstrable. This breaking through may give the field an irregular crescentic, or sometimes pseudo-hemianopic appearance. Later the periphery may recover more or less all round, leaving a central scotoma.

The defect is peri-central rather than para-central or centro-caecal, though it often includes the blind spot and the intensity is usually high. According to the severity of the case, all degrees of size, intensity and permanence may result. In the worse cases little or no recovery may take place; in the milder ones normal vision may be restored. This stage is unfortunately frequently succeeded by a second and permanent loss of vision associated with pallor of the optic disc. The field becomes depressed and contracted; Goldflam noted a return to blindness in a case which had reached normal vision. Only exceptionally does good vision return and remain when the field changes have been severe to begin with.

The field changes indicate the action of a violent poison on the retinal cells and optic nerve with special selectivity for the central elements. The ultimate deterioration of vision following primary recovery is probably due to a cicatricial process in the nerve depending on the violence of the reaction, leading to secondary atrophy.

The diagnosis depends upon the clinical picture as a whole, which usually suggests this kind of poisoning: the prognosis should be guarded at first, even although the field defects have greatly improved, as secondary atrophy may supervene. The field should therefore be watched for some time after apparent recovery."

Histological findings in the Retina

Four retinae were available for histological study. The retina was first examined in bulk, stained with scharlach red, and mounted in glycein. By this means it is possible to examine the whole retina at once and to examine it in layers for fatty changes. With high power, and with the diaphragm cut down, it is possible to examine the ganglion cells minutely, and by continuous movement of the focusing adjustment of the binocular microscope, details of contour are enhanced by the stereoscopic effect. This is the dynamic microscopy technique (Loewenstein).

In all cases the ganglion cells contained fatty droplets to such a degree as to be apparent in (Fig. 1 x 50) with low power. This appears as in (Fig. 2, x 300) with higher power. The ganglion cells are full of dark red droplets and the big ganglion cells are almost exclusively affected. The droplets are of different size, the smallest scarcely recognisable with the (x 600) power, and the largest are about one-tenth of the size of an erythrocyte. With the method of staining retina in bulk with scarlet red, we recognise that the capillaries show, quite markedly, lipid droplets in the walls (Fig. 3). In a common investigation with Loewenstein (*Brit. Jl. of Ophthalm.*, 1943), we have studied these changes in the retinal ganglion cells in different decades of life. We found these fatty changes in the ganglion cells of the aged but they were very obvious even in the middle-aged. Only the retina of youth is free of them. This corresponds with the findings of Obermeyer, quoted secundum Spielmeier. In many papers on brain histology this author found that senile ganglion cells, especially in the anterior horn, and Clark's columns, contained fatty corpuscles regularly increasing in incidence as age advanced. In the brain, however, these lipid droplets are recognisable from the early age of eight years, until in extreme age the cells are filled with droplets. In our paper we prove that the condition in the retina is analogous. We can say that the lipid changes we have found in these cases of the fourth decade suffering from methyl alcohol poisoning are no more marked than those we find in normal retinae of the same age, nor yet are the fatty infiltrates in the capillary wall more pronounced than those in the normal, similar age group.


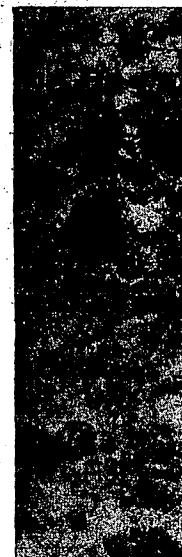


FIG. 1 (x50).

Lipoid changes in retinal ganglion cells, with low power, stained with scarlet red (photomicro).




Lipoid changes in retinal with scarlet red. Note nuclear counterstain (photo)



Lipoid changes in the em (photomicro)

EGOR

ed fatty droplets to such
0) with low power. This
er power. The ganglion
he big ganglion cells are
ets are of different size,
ne (x 600) power, and the
of an erythrocyte. With
scarlet red, we recognise
ly, lipoid droplets in the
on with Loewenstein (*Brit.*
ese changes in the retinal
e. We found these fatty
d but they were very ob-
he retina of youth is free
findings of Obermeyer,
papers on brain histology
ells, especially in the an-
ned fatty corpuscles regu-
nced. In the brain, how-
ble from the early age of
ls are filled with droplets.
in the retina is analogous.
have found in these cases
hyl alcohol poisoning are
ormal retinæ of the same
the capillary wall more
imilar age group.



th low power, stained with

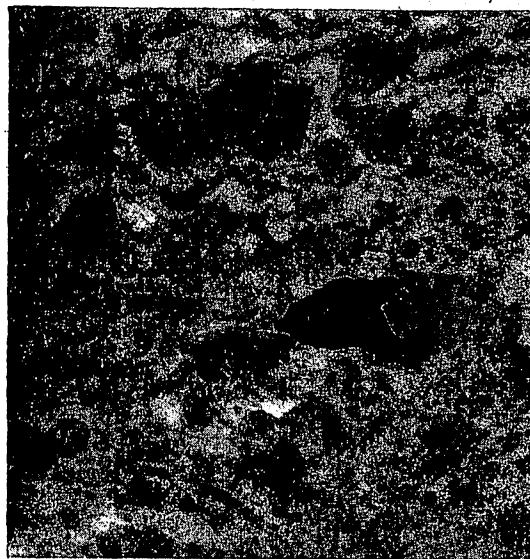


FIG. 2 (x300).

Lipoid changes in retinal ganglion cells, with high power, stained with scarlet red. Note the nuclear differentiation. There was no nuclear counterstain (photomicro).

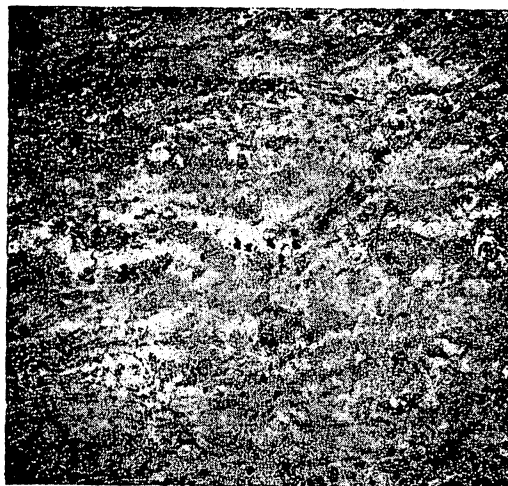


FIG. 3 (x50).

Lipoid changes in the empty capillary wall, stained with scarlet red (photomicro)

In each retina there was an area of gross droplet deposition situated about half-way between the disc and the periphery, but in no case at the macula. This area was trephined, mounted in gelatine, and sectioned. The fatty droplets were large and extracellular. They were situated mostly in the ganglion cell layer but some were in the outer molecular layer. They frequently showed a biphasic staining reaction with scharlach red, part of the droplet being dark purple and the remainder bright red. The significance of this we do not yet know. It would be unwise to attach importance to this appearance of gross extracellular droplet formation. One would expect a change consequent on a diffusible circulating poison to be diffuse, not localised and intense. We feel that it is best regarded as post-mortem change.

The choroid was examined in bulk and fatty changes were found in the pigment cells with changes also in the capillary walls.

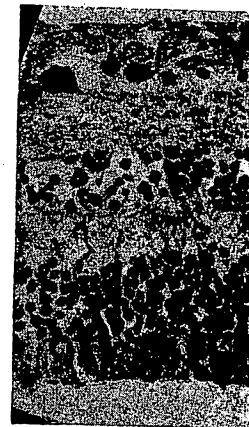
We believe that the technique of examination of the retina in bulk allows us to appreciate the size and shape of the ganglion cells and their minute structure better than by routine methods. There is no distortion from fixation and embedding. One can examine the cell in depth and get a stereoscopic picture.

Some of the giant cells have a diameter of 30 μ . The smaller ones are little larger than the rod bipolar. After examining hundreds of ganglion cells in our cases of alcohol poisoning we found most of them to have a clear regular cell outline. The cytoplasm was granular. This granular appearance was most striking in the giant cells. The nucleus was clearly defined, and frequently, the nucleolus. A proportion had not a clear cell outline, in some no nucleus could be seen. These same variations we found in our scrutiny of normal retinæ of the same age.

Pick and Bielschowsky found the large ganglion cells showed a change in the arrangement of Nissl granules in the nucleus in their routine haemalum and eosin sections. They found that the granules were normally arranged coronally in the nucleus, while in their poisoning cases they were arranged in ill-defined clumps. They found that the fibre layer was fragmented and disintegrated. They thought that the inner nuclear layer stained more intensely, and changes in the nerve were inconsiderable. McDonauld found that the ganglion cells were swollen and the fibre layer was thickened. Menne made similar observations also on routine haemalum and eosin sections.

Clinically, as we have said above, the fundal changes in life are oedema of the nerve head and of the retina. Where this occurs one would expect the fibre layer to be thickened and less compact. But clinically there may be no fundal changes. It is our routine, when circumstances permit, to inject a few minims of 8 per cent.

formol saline into the vitreous as possible. We were not. The fibre layer consequently interstices in the layer and in mind then, we would not of thickness of the fibre layer integrity of the fibres was no sion of early intra-ocular fixation our routine haemalum and eosin mounted and not compact. A



FIG

Routine section cut in paraffin and eosin (photomicro).

post-mortem autolysis in the retina. We have not had the privilege of making sections and we certainly do not in their examination of routine sections. In methanol poisoning of the retina, the micrographs.

We would like to show a photomicrograph of sections in which so many shapes of ganglion cells have no nucleus. Some are swollen and some are normal. In retinæ other than in normal ones. The slight change in the fibre layer was adequately explained (Fig. 4).

We have attached more signi-

gross droplet deposition
and the periphery, but
s trephined, mounted in
ets were large and extra-
the ganglion cell layer
ayer. They frequently
scharlach red, part of
mainder bright red. The
It would be unwise to
ross extracellular droplet
consequent on a diffus-
calised and intense. We
change.
nd fatty changes were
s also in the capillary

ination of the retina in
shape of the ganglion
un by routine methods.
embedding. One can
scopic picture.

of 30 u. The smaller
ar. After examining
f alcohol poisoning we
lar cell outline. The
appearance was most
as clearly defined, and
ad not a clear cell out-
ese same variations we
the same age.

ganglion cells showed
ules in the nucleus in
They found that the
n the nucleus, while in
in ill-defined clumps.
nted and disintegrated.
ed more intensely, and
McDonald found that
e layer was thickened.
outine haemalum and

dal changes in life are
. Where this occurs
ned and less compact.
es. It is our routine,
minims of 8 per cent.

RETINAL AND VISUAL FIELD CHANGES IN ACUTE METHYL ALCOHOL POISONING

535

formol saline into the vitreous of the cadaver as soon after death
as possible. We were not able to do this in our alcohol cases.
The fibre layer consequently does not cut so well and there are
interstices in the layer and the fibres are fragmented. With this
in mind then, we would not venture to dogmatise on the question
of thickness of the fibre layer or to say that the ante-mortem
integrity of the fibres was not in doubt. We think that the omis-
sion of early intra-ocular fixation may account for the fact that in
our routine haemalum and eosin sections the fibre layer is frag-
mented and not compact. As Eugene Wolff so rightly stresses,



FIG. 4 (X200).

Routine section cut in paraffin and stained with haemalum and
eosin (photomicro).

post-mortem autolysis in the retina is frequent and rapid.
We have not had the privilege of seeing McDonald's or Menne's
sections and we certainly do not wish to dispute their findings in
their examination of routine haemalum and eosin sections in
methanol poisoning of the retina on the evidence of their photo-
micrographs.

We would like to show a photomicrograph of our routine sec-
tions in which so many shapes and sizes of ganglion cells appear.
Some are swollen and some are shrunken. In other slides some
ganglion cells have no nucleus. But we have seen all those vari-
ations in retinae other than in alcohol poisoning cases, even in
normal ones. The slight change in compact structure of the fibre
layer was adequately explained by the absence of pre-fixation
(Fig. 4).

We have attached more significance to the conclusions we have

been able to draw from examination of the ganglion cells in retina in bulk than to our routine sections.

Finally the nerve was stained in serial section, every fortieth section, by Weigert's haematoxylin and nothing of note was found. This was followed by Marchi's technique which gave a slight Marchi positive of an unconvincing appearance. We stained a control nerve with Marchi and another piece of the same control which, in addition to the trauma of removal from the skull, was traumatised by leaving it under a weight of 14 lbs. for 24 hours. The nerve from the spirit poisoning patient and the normal control were identical. The traumatised control nerve showed some Marchi positive staining at the periphery. We did not think there was any evidence of degenerative changes in the myelin content of the nerve in our cases of methyl alcohol poisoning.

Changes in the Field of Vision in Methyl Alcohol Poisoning

After the lapse of a year we considered that the damage done to the eyes of those people who survived the poisoning would possibly be stable. Accordingly we summoned all of them several times to be examined. The hours of examination were arranged after working hours but the demands of war industries made it impossible for us to review more than four cases. They were seen on two occasions. We give the history and findings in each case.

CASE I.—Mr. P.M., aged 33 years, had at least two ounces of spirit, well diluted. Legs were weak, no abdominal pains, haze over the eyes for a day. On this day his discs were described as reddish with blurred margin. On May 1, 1942, they were described as normal and vision on the optometer was, right eye—6/12, and left eye—6/12. On April 12, 1943, his fields of vision were perfectly full with two isopters, 7/330 and 3/330 white. His colour field was normal. There was no relative scotoma. His corrected vision was, right eye—6/9 and left eye—6/6. His fundi were normal.

CASE II.—Mr. J.D., aged 64 years, drank three ounces of industrial alcohol. Soon after he had pains and cramps and yellow vision. Semi-comatose on admission. Vision gradually got worse. It was, right eye—hand movements; and left eye—fingers at 2 feet; on the day after admission, *i.e.*, April 27, 1942. The fundi were normal. The following day the discs had blurred margins and there was oedema of the retina spreading down from the disc. The right pupil responded slightly to light and the left was dilated and inactive.

On April 28, 1942, there was a central scotoma in both eyes, worse in the left eye. Vision was, right eye—hand movements; and left eye—perception of light. On April 29, 1942, central

scotoma was complete for 10 minutes. Hand movements, and left eye—fingers at 2 feet. On May 2, 1942, vision was, right eye—6/12, and left eye—6/12. When seen a year later his vision was, right eye—6/60 correctable to, right eye—6/12, and left eye—6/12. His Wassermann reaction was negative. There was slight narrowing of the arteries. A:V=1:2. Some nipping at the periphery. The fundi showed bluish pallor and we

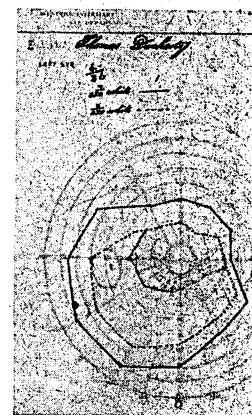


FIG. 1

Fields of vision after

tension was normal. No sheath was greatest temporally and the moth-eaten or nibbled appearance. Pigment was scattered round the left macula showed pigmentary curious patchy irregular reflex, lamp. In the periphery of both fundi there was a white pigmentary deposit with occasional white dots. He volunteered to serve in his third factory, but they found out his age and he was not allowed to work for glasses since he left hospital. He was given a number on the Ishihara plates.

His peripheral field is shown in hatching the right eye, and green vision outlined in the left

anglion cells in retina
section, every fortieth
nothing of note was
unique which gave a
g appearance. We
ther piece of the same
removal from the skull,
ght of 14 lbs. for 24
patient and the nor-
control nerve showed
shery. We did not
changes in the myelin
alcohol poisoning.

n Methyl

hat the damage done
poisoning would pos-
l all of them several
on were arranged after
stries made it impos-

They were seen on
dings in each case.
t least two ounces of
dominal pains, haze
scs were described as
1, 1942, they were
eter was, right eye—
}, his fields of vision
nd 3/330 white. His
lative scotoma. His
eye—6/6. His fundi

unk three ounces of
id cramps and yellow
sion gradually got
and left eye—fingers
April 27, 1942. The
e discs had blurred
preading down from
to light and the left

otoma in both eyes,
—hand movements;
ril 29, 1942, central

scotoma was complete for 10mm. white spots. Vision, right eye—
hand movements, and left eye—fingers at 2 feet. On April 30,
1942, vision, right eye—fingers at 2 feet, and left eye—fingers at
5 feet. On May 2, 1942, vision, right eye—4/9 and left eye—4/18.
When seen a year later his vision was, right eye—6/60 and left
eye—6/60 correctable to, right eye—6/24 and left eye—6/36. Pupils
were equal but reacted sluggishly to light and briskly to near.
His Wassermann reaction was negative. The fundi showed some
slight narrowing of the arteries, the preponderant ratio being
A:V=1:2. Some nipping and bending of veins. Both discs
showed bluish pallor and well marked cup. His intra-ocular

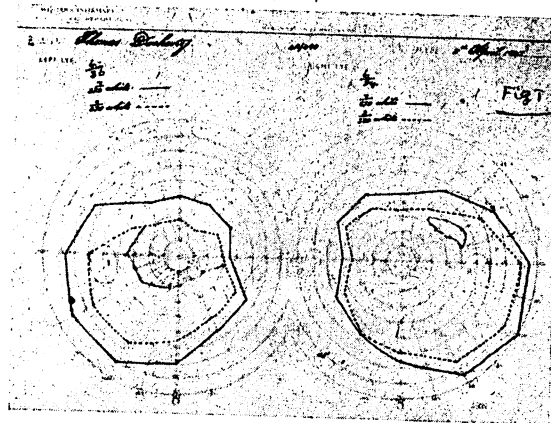


FIG. 5 (CASE 2).

Fields of vision after methyl alcohol poisoning.

tension was normal. No sheathing of vessels at the disc. Pallor
was greatest temporally and the choroid was thinned and had a
moth-eaten or nibbled appearance on the temporal side of the disc.
Pigment was scattered round the temporal side of the disc. The
left macula showed pigmentary change and the retina showed a
curious patchy irregular reflex, best seen with the mercury vapour
lamp. In the periphery of both fundi there was a fine pigmen-
tary deposit with occasional white spots. He states that in 1939 he
volunteered to serve in his third war and his eyesight was satis-
factory, but they found out his age. He has tried several opticians
for glasses since he left hospital last year. He cannot read any
number on the Ishihara plates.

His peripheral field is shown in (Fig. 5), with red-green scotoma
in hatching the right eye, and the only remaining island of red-
green vision outlined in the left eye. In (Fig. 6) the relative

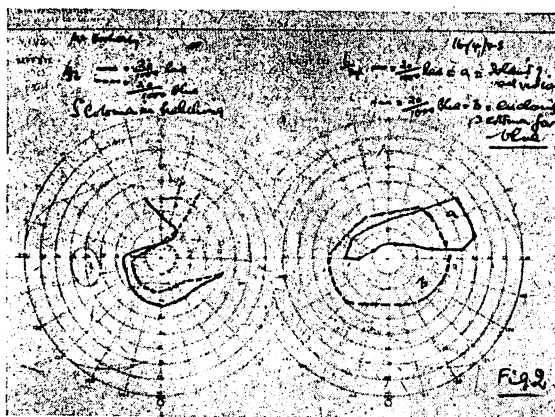


FIG. 6 (CASE 2). Screen field.
Fields of vision after methyl alcohol poisoning.

scotoma was recorded on the screen showing in the right eye central scotoma for 20/1000 red and blue, breaking through to the nasal side; in the left eye (b) is the area of scotoma for 20/1000 blue and (a) enclosed by interrupted line, is the remaining island of vision for 20/1000 red-green.

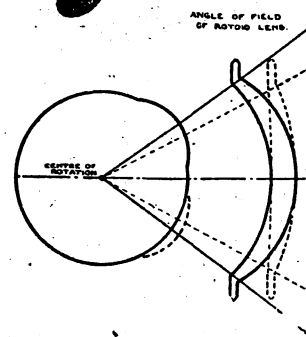

CASE III.—Mr. B.M., aged 46 years. This patient was in hospital for a cement burn of the left eye in 1939. His vision then on dismissal was, right eye—6/9 and left eye—6/9. He had about an ounce and a half of methanol in a pint of water. He had pains in the abdomen and mistiness of vision. His vision was reduced to perception of light. He vomited shortly after drinking the spirit. On April 28, 1942. Small corneal opacity, left eye, not interfering with vision. Both pupils active and fundi within normal limits. On April 29, 1942, vision was, right eye—6/9, and left eye—6/60.

Central scotoma left eye. Right eye—Isihara normal; left eye—no letters seen entirely, upper part seen sometimes. Large scotoma in lower half of field. On May 15, 1942, vision, right eye—6/9, and left eye—1/60. The left disc shows temporal pallor. There is a large scotoma to 5/1000 white.

On April 12, 1943, a year later, vision was, right eye—6/9, and left eye—1/60. Both pupils reacted normally. The right fundus was normal. The left disc was pale and cupped, the vessels showed no sheathing, and there was pigmentary deposit on the outer side with choroidal thinning similar to that seen in the preceding case. His peripheral fields were normal for 7/330 and 3/330 white. The central scotoma in the left eye has not appreciably changed;



"Re which have powered co also where cor The wide field p the diagram at th





XTON Ltd.

STREET
WIDON. W.I.

GOW • LIVERPOOL
AND • SOUTHPORT

cope



Retinoscope which
is a duplicate
as suggested by

£3 3s.

RETINAL AND VISUAL FIELD CHANGES IN ACUTE METHYL ALCOHOL POISONING

539

it is absolute for 3/1000 white over 8°. Most of the central colour field has gone; there is a little patch of red-green vision up and in. The central and peripheral field in the right eye are normal.

CASE IV.—Mr. J.H., aged 49 years. Probably drank as much as six ounces diluted in beer and coffee over two days. He was very confused and cyanosed. Everything looked yellow. Both pupils dilated to diameter of 4 mms. but reacted to light. On admission both discs were reddish. At 6 p.m. of the same day the right fundus showed fullness of the veins, oedema of the nerve head with diffuse oedema of the retina, spreading from the disc all round. On the following day, April 29, 1942, the picture was unchanged. Central vision with optometer was unsatisfactory. He stated that vision was blurred, especially to the outer side of the field, in each eye. There was a relative colour scotoma down and out in the right eye, but in the left eye he read Jaeger 10 very slowly.

On May 1, 1942, vision in the right eye—6/18, left eye—6/36. On May 2, 1942, vision in the right eye—6/18, left eye—6/60. Relative colour defect down and out, left eye relative blindness to red, spot below one year later. On April 8, 1943, vision in the right eye—6/9, left eye—6/24 corrected, right eye—6/6, left eye—6/12. Pupil reaction normal. He can read Ishihara correctly with the right eye, but only a few of the numbers with the left eye. The fields of vision are as in (Fig. 7). The left field showed a hemianopic type of defect, especially with the inner isopter 3/330 white, and there was a red-green central scotoma for 7/330 as in the area of hatching. The right peripheral field was normal for




FIG. 7 (CASE 4).

Fields of vision after methyl alcohol poisoning.

7/330 and 3/330 white and the central field was normal. Both discs were pale on the temporal side but the left much more markedly. There was no cupping. There was no sheathing. The veins were slightly full, the ratio being frequently $A:V=1-2$. In the affected eye there was the same phenomenon of pigment scatter at the temporal side of the disc with the nibbled or moth-eaten appearance of the choroid. The normal eye did not show this.

Discussion

Fundal changes are not always present in the early stages of methanol poisoning but they are of a consistent nature. Haziness of the disc margins, engorgement of the veins, and in more marked cases, oedema of the retina spreading from the disc, is the picture presented in the literature. Of the four cases whose fields we discuss the first had slight changes in the disc and two others had changes in the disc and oedema of the retina. Nowhere in the literature have we found a description of oedema of the retina and a normal disc. The fundal changes centre round the nerve head. The first case had changes in the disc and impaired vision. He recovered. The second was blind and had a bilateral central scotoma in the early days of recovery. He had marked fundal changes. A year later he had a relative central scotoma with impaired vision in both eyes. The third case had no record of fundal changes and a central scotoma in the left eye during the early days of recovery. A year later his right eye was normal and the left eye showed an absolute central scotoma with vision grossly reduced. All three had fields of normal peripheral extent.

The last case had marked bilateral fundal changes, with scotomata in both eyes in the early stages of recovery and a year later the visual acuity and field of vision were normal in one eye and in the other there was some nasal peripheral loss; indeed the inner isopter had an approximately hemianopic appearance, with a relative central colour scotoma for red and green. His visual acuity was a little impaired in this eye.

Some authors have found that the outlook was almost uniformly bad as far as useful central vision was concerned. Our follow-up series is very short, but as far as we see from a year's observation, and perhaps even this is not long enough, the outlook is not altogether bad. Only one man has an absolute scotoma in one eye, the other being normal; another, a relative colour scotoma with peripheral loss in one eye, and the other eye normal; another, no defect that we could discover; and another, a bilateral relative scotoma. They all had a considerable amount of spirit, as can be seen from the case histories. As we mention above, however, the estimation of how much spirit was drunk is only approximate in most papers. The ophthalmoscopic appearances in those four men were

interesting. Where vision the disc was pale and cupped where the visual loss was scotoma had a very deep cup. Where the nerve was profuse where there was slight loss side. It is interesting to the right eye had normal colour scotoma with periphery quite marked in both, although.

We appreciate that it is temporal pallor, but we think case. It interested us that it called to mind those cases where vision returns but the papillary atrophy and cupping have. The atrophy was simple; the

Another point interested us the eye which had suffered the choroid on the temporal side eaten or nibbled, with pigment in every eye which was in. Bearing in mind the frequency side of the disc as a simple sign of cal significance, we thought not a finding of great significance control to interpret the appearance characteristic for us to be on to the papillo-macular bundle in the literature.

Most of the cases that of an evanescent nature, chronic ones originating in infections, lactation, avitaminosis have admitted of histological affected while the rest of is a central scotoma. This is produced by an embolism thrombosis or ischaemia, or centre of the nerve is said to be vessels from the pial network quoted as a factor in the frequency in disease. Alcohol is a vasodilator slowly eliminated. The vasodilation No appreciable change was noted. Menne in his paper on the

s. normal. Both discs
much more markedly.
ing. The veins were
=1-2. In the affected
ent scatter at the tem-
h-eaten appearance of
is.

n the early stages of
ent nature. Haziness
, and in more marked
ne disc, is the picture
ases whose fields we
disc and two others
retina. Nowhere in
oedema of the retina
ntre round the nerve
and impaired vision.
had a bilateral central
e had marked fundal
central scotoma with
ase had no record of
e left eye during the
t eye was normal and
na with vision grossly
ipheral extent.

changes, with scoto-
very and a year later
ormal in one eye and
eral loss; indeed the
opic appearance, with
d green. His visual

was almost uniformly
rned. Our follow-up
a year's observation,
ne outlook is not alto-
otoma in one eye, the
ur scotoma with peri-
nal; another, no defect
eral relative scotoma.
, as can be seen from
wever, the estimation
imate in most papers.
those four men were

interesting. Where vision was impaired and the field affected, the disc was pale and cupped. Cupping was the more marked where the visual loss was greatest. The man with the complete scotoma had a very deep cup. His intra-ocular pressure was normal. Where the nerve was profoundly affected, it was uniformly pale; where there was slight loss, the pallor was marked on the temporal side. It is interesting to note here that in the last case where the right eye had normal vision and field, and the left a relative colour scotoma with peripheral nasal loss, temporal pallor was quite marked in both, although more so in the left eye.

We appreciate that it is difficult to be dogmatic always about temporal pallor, but we thought it was quite appreciable in this case. It interested us that it should be present in the normal eye. It called to mind those cases of retrobulbar neuritis in which the vision returns but the pallor remains. The facts of the late atrophy and cupping have often been described in these cases. The atrophy was simple; there was no glial proliferation.

Another point interested us in the examination of the discs. In the eye which had suffered impairment of vision or field, the choroid on the temporal side of the disc looked thin and moth-eaten or nibbled, with pigment scatter. This appearance was seen in every eye which was impaired but not in the normal eyes. Bearing in mind the frequent appearance of pigment at the other side of the disc as a simple structural variation without pathological significance, we thought that this was rather different. It is not a finding of great significance, and we have no histological control to interpret the appearance, but it was sufficiently characteristic for us to be on the lookout for it in cases of damage to the papillo-macular bundle. We have not found it described in the literature.

Most of the cases that we see of retrobulbar neuritis are of an evanescent nature, tending to recover quickly. The chronic ones originating in diabetes, the anaemias, the acute infections, lactation, avitaminosis, and so on, while they are rarer, have admitted of histology. The papillo-macular bundle is affected while the rest of the nerve escapes and the defect is a central scotoma. The question arises as to whether this is produced by an effect on the blood vessels with thrombosis or ischaemia, or primarily on the neurone. The centre of the nerve is said to be less well supplied with blood vessels from the pial network than the periphery, and this is quoted as a factor in the frequent affection of the central bundle in disease. Alcohol is a vasodilator. Methyl alcohol is very slowly eliminated. The vasodilator action is therefore prolonged. No appreciable change was noted in the retinal arteries.

Menne in his paper on the complete post-mortem examination

of 22 cases of death from methanol poisoning speaks of the remarkably negative findings in the central nervous system, apart from oedema. He suggests that this is really not surprising when death occurs so soon after poisoning, and directs our attention to the experimental work in which animals have been poisoned over periods up to a year and the central nervous system examined. He quotes Scott and his co-workers who conclude that vascular damage was slight, and parenchymal and neuronal tissue were affected by the poison. It may well be that the oedema which we see in the nerve head is the effect of the poison on the conducting neurone of the papillo-macular bundle.

The oedema which Menne describes is probably not inflammatory, but passive. The difficult point is the occurrence of simple atrophy without sheathing of the vessels. The common passive oedema of the disc is plerocephalic oedema and this is a much more sustained process than the comparatively transient oedema that we are considering. It is much more understandable that papilloedema should provoke glial formation because it is often present for weeks, or even months perhaps, before it is diagnosed.

However, when we come in conclusion to consider the histopathological findings in the cases who died of acute poisoning, there is a further possibility to be considered. By the use of routine staining methods and by examination of the retina in bulk, we were of the opinion that in our cases there were no changes characteristic of methanol poisoning. From this and collateral studies with Loewenstein (quoted above), of the ganglion cells of the retina in health and disease, we would not like to say that they are altered to any great extent, either in shape or in size, cytoplasmic structure, nuclear content, or structure, or in the lipid change which they exhibit. We have examined many hundreds of ganglion cells in our cases of spirit poisoning and in normal retinæ of most decades and we find no substantial difference between the normal retinal ganglion cells of the fourth decade and our methanol poisoning cases which were in the fourth decade. It may be that the thickening of the fibre layer described by other authors was due to the oedema that we see clinically. Where the vitreous is not injected with formol-saline soon after death the fibre layer tends to be fragmented and loose. Post-mortem autolysis in the retina is very rapid. We would like to say, as Menne said of his findings generally, that it would perhaps be unwise to put too much stress on negative histological findings in such an acute poisoning. Had the patients lived some weeks instead of some hours, we might be able to say histologically that the poison attacked either the ganglion cell, or the neurone in the nerve primarily. By that time the evidences of decay would be

there for us to see. The fact is no proof that their physiological impairment might later lead to a loss of continuity of the neurone in the optic nerve.

An outbreak of acute methanol poisoning was described. The retina was stained with haemalum and eosin staining in bulk after staining with safranin and sectioning of the bulk prepared. The retinal ganglion cells were stained to acute methyl alcohol poisoning. There were changes in the ganglion cells, but not in the optic nerve cells or the nuclear cells.

The optic nerve in each case was stained with haematoxylin and by a rapid stain for myelin, Weigert-Pal. The optic nerve in each case was examined after a short time. One had no definite acute stage. One had a relative scotoma, the third a normal, and the last a relative scotoma and the other eye normal.

In cases succumbing so soon, the evidences are few. Those evidences are not sufficient to show whether the primary damage is to the optic nerve or the ganglion cells. Review of the cases described suggests that the damage is to the nerve.

REFERENCES

- BALLANTYNE.—*Brit. J. Ophthalmol.*, Vol. I.
DUKE-ELDER.—*Text-Book of Ophthalmology*.
ELEONSKAJA.—*Russ. Ophthalmol. J.*, Vol. I.
HAGGARD, H. W. and GREENBERG, J.—*Therapeut.*, Vol. LXVI, pp. 4-6.
HIRSCHBERG.—*Centralblatt. f. prakt. Ophthalmol.*, Vol. III.
JACKSON.—*Amer. J. Ophthalmol.*, Vol. III.
LOEWENSTEIN, ARNOLD.—*Arch. of Ophthalmol.*, Vol. I.
MCCLEUNG.—*Microscopical methods*, p. 10.
MCDONALD.—*Thirteenth International Congress of Ophthalmology*.
MENNE, FRANK R.—*Arch. of Pathol. and Bacteriol.*, Vol. I.
PICK and BIELSCHOWSKY.—*Klin. Wochenschr.*, 1912, No. 129.
ROUSSY and LHERMITTE.—*Quoted by C. Simons*.
SIMONS.—*Amer. J. Ophthalmol.*, Vol. XXV.
SMITH and QUIGLEY.—*Amer. J. of Pathology*.
STADELMAN and MAGNUS LEWY.—*Med. J.*
SWANK and DAVENPORT.—*Quoted by C. Traquair*.
TRAQUAIR, H. M.—*An Introduction to Clinical Ophthalmology*.
WOLFF, EUGENE.—*Personal communication*.

RETINAL AND VISUAL FIELD CHANGES IN ACUTE METHYL ALCOHOL POISONING

543

there for us to see. The fact that the ganglion cells looked normal is no proof that their physiology was not impaired and that the impairment might later lead to death of the cell, with an atrophy in continuity of the neurone in the nerve.

Summary

An outbreak of acute methyl alcohol poisoning in Glasgow is described. The retina was examined in four cases by routine haemalum and eosin staining and by the method of examination in bulk after staining with scarlet red and thereafter embedding and sectioning of the bulk preparation in gelatin. No changes in the retinal ganglion cells which could be attributed indubitably to acute methyl alcohol poisoning were found, either in the lipoid changes in the ganglion cells, or in the size and shape of the ganglion cells or the nuclear content.

The optic nerve in each case was examined in serial section stained with haematoxylin and eosin, and by Marchi's method and by a rapid stain for myelin (Smith and Quigley) instead of Weigert-Pal. The optic nerves showed no abnormality. Four cases were examined after a year. They had been blind in the acute stage. One had no defect in vision, the second a bilateral relative scotoma, the third an absolute scotoma and his other eye normal, and the last a relative scotoma with good vision in that eye and the other eye normal.

In cases succumbing so soon after poisoning, histological evidences are few. Those evidences in acute poisoning are not sufficient to show whether the retinal tissue or the nerve tissue primarily succumbs. Review of the literature and the follow up of the cases described suggest that the poison acts on the centre of the nerve.

REFERENCES

- BALLANTYNE.—*Brit. Jl. Ophthal.*, Vol. I, p. 153, 1917.
DUKE-ELDER.—*Text-Book of Ophthalmology*, Vol. III, p. 3032.
ELEONSKAJA.—*Russ. Ophthal. Jl.*, Vol. IV, p. 40, 1925.
HAGGARD, H. W. and GREENBERG, L. A.—*Jl. of Pharmacol. and Exper. Therapeut.*, Vol. LXVI, pp. 479-496, 1939.
HIRSCHBERG.—*Centralblatt. f. prakt. Augenheilk.*, seite 44, 1912.
JACKSON.—*Amer. Jl. Ophthal.*, Vol. III, p. 150, 1920.
LOEWENSTEIN, ARNOLD.—*Arch. of Ophthal.*, Vol. XXVII, pp. 73-90, 1942.
MCCLUNG.—*Microscopical methods*, p. 493, 1937.
MCDONALD.—*Thirteenth International Congress*, Amsterdam, p. 440, 1939.
MENNE, FRANK R.—*Arch. of Path.*, Vol. XXVI, pp. 79-92, 1938.
PICK and BIELSCHOWSKY.—*Klin. Wochen. Berl.*, seite 888, 1912.
KOST.—*Med. Klin. Berl.*, seite 129, 1912.
ROUSSY and LHERMITTE.—Quoted by Carleton's *Histol. Tech.*, 1938.
SIMONS.—*Amer. Jl. Ophthal.*, Vol. XXV, pp. 446-451, 1942.
SMITH and QUIGLEY.—*Amer. Jl. of Path.*, Vol. XIII, pp. 491-496, 1937.
STADELMAN and MAGNUS LEWY.—*Med. Klin. Berl.*, seite 127, 1912.
SWANK and DAVENPORT.—Quoted by Carleton's *Histol. Tech.*, 1938.
TRAQUAIR, H. M.—*An Introduction to Clinical Perimetry*, p. 153, 1938.
—*Trans. Ophthal. Soc. U.K.*, Vol. L, p. 351, 1930.
WOLFF, EUGENE.—*Personal communication*.