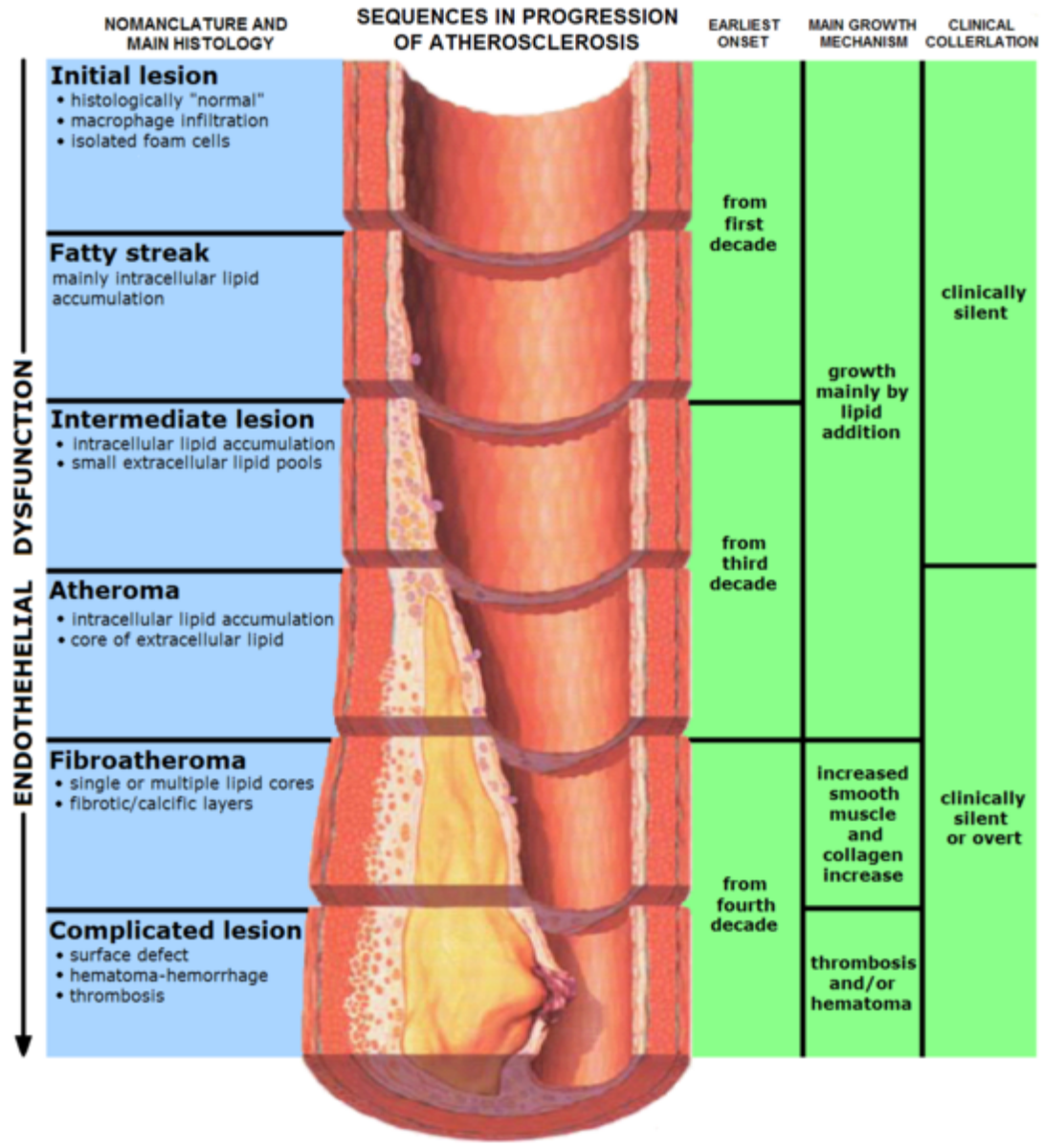
NOMANCLATURE AND MAIN HISTOLOGY
SEQUENCES IN PROGRESSION OF ATHEROSCLEROSIS
EARLIEST ONSET
MAIN GROWTH MECHANISM
CLINICAL COLLERLATION
ENDOTHEHELIAL DYSFUNCTION
Initial lesion
• histologically "normal"
• macrophage infiltration
• isolated foam cells
Fatty streak
mainly intracellular lipid accumulation
Intermediate lesion
• intracellular lipid accumulation
• small extracellular lipid pools
Atheroma
• intracellular lipid accumulation
• core of extracellular lipid
Fibroatheroma
• single or multiple lipid cores
• fibrotic/calcific layers
Complicated lesion
• surface defect
• hematoma-hemorrhage
• thrombosis
from first decade
from third decade
from fourth decade
growth mainly by lipid addition
increased smooth muscle and collagen increase
thrombosis and/or hematoma
clinically silent
clinically silent or overt