

Their
Choice

FILE COPY

Ion Gap

TOXICOLOGY AND APPLIED PHARMACOLOGY 45, 201-208 (1978)

Methanol Poisoning: Ocular Toxicity Produced by Formate¹

G. MARTIN-AMAT, K. E. McMARTIN, S. S. HAYREH, M. S. HAYREH, AND
T. R. TEPHLY

The Toxicology Center, Department of Pharmacology, and Department of Ophthalmology, The University
of Iowa, Iowa City, Iowa 52242

Received October 26, 1977; accepted December 22, 1977

Methanol Poisoning: Ocular Toxicity Produced by Formate. MARTIN-AMAT, G., McMARTIN, K. E., HAYREH, S. S., HAYREH, M. S. AND TEPHLY, T. R. (1978). *Toxicol. Appl. Pharmacol.* 45, 201-208. After methanol administration, monkeys developed optic edema, acidosis, and formate accumulation in blood. Formaldehyde was not measurable in any fluids or tissue. Experiments were designed to study the possible role of formate in ocular toxicity. Formate was administered by iv infusion in the form of formate buffer for the purpose of maintaining pH in the normal range. The rate of formate infusion was adjusted to maintain blood formate at toxic concentration. No formaldehyde was detected. Results were similar to those described for methanol poisoning: optic disc edema with a normal vascular bed and intracellular edema with intraaxonal swelling.

Formate
Methanol
Formaldehyde
Acidosis
ION-GAP
eye.

K.W, Ion Gap, Formate, Formaldehyde

Methanol poisoning in man and in monkeys is characterized by severe metabolic acidosis and marked ocular toxicity (Roe, 1943; Benton and Calhoun, 1953; Gilger and Potts, 1955; McMARTIN *et al.*, 1975; Clay *et al.*, 1975; Martin-Amat *et al.*, 1977a; Hayreh *et al.*, 1977; Baumbach *et al.*, 1977). Recently, several laboratories have reported the accumulation of formic acid in the blood of monkeys which had become severely acidotic after the administration of methanol (McMARTIN *et al.*, 1975; Clay *et al.*, 1975; Martin-Amat *et al.*, 1977a). In fact, those authors have reported on decreases in blood bicarbonate concentrations which equate with elevated blood formate values. It would appear that formic acid accumulation is responsible for metabolic acidosis produced in methanol poisoning in the monkey.

What about
Mc Martin
1975
(an Iowa City)
boy

The ocular toxicity produced after methanol administration in monkeys has recently been explored. Monkeys maintained on an experimental regimen with blood formate values of about 10 mEq/liter and arterial blood pH values of 7.1 to 7.3 (Martin-Amat *et al.*, 1977a) consistently had serious optic disc edema and loss of the pupillary response to light (Hayreh *et al.*, 1977). The optic disc edema appears similar to the ocular toxicity described in humans (Benton and Calhoun, 1954). Histopathologic evaluation of the optic nerves (Baumbach *et al.*, 1977) showed intraaxonal swelling in the anterior segment of the optic nerve with otherwise normal retinae, including normal ganglion cells.

Since elevated formate concentrations occurred in the presence of metabolic acidosis in animals displaying ocular toxicity, we tested the possibility that formate alone was

¹ This work was supported by the National Institutes of Health Grant GM12675.

204
207

Monkey
yes

Man
no

Iowa
City

responsible for the optic disc edema seen in methanol poisoning and that acidosis played either no role or only a secondary role in the development of the ocular lesion. We report the formation of marked optic disc edema in every monkey treated with sodium formate, where arterial blood pH was within physiologic limits, and we wish to draw attention to the fact that the lesions produced by formate were essentially identical to those seen previously when methanol was administered to monkeys (Martin-Amat *et al.*, 1977a; Hayreh *et al.*, 1977; Baumbach *et al.*, 1977).

METHODS

Male rhesus monkeys (*Maccaca mulatta*) weighing from 3.2 to 5.5 kg were intoxicated by intravenous formate infusion. Formate buffers [sodium formate:formic acid, 10:1 (0.5 M)] were infused after a loading dose of 1.25 mmol/kg sodium formate. The rate of infusion was calculated to produce concentrations of formate similar to those seen in methanol-intoxicated monkeys in which ocular toxicity was produced (Martin-Amat *et al.*, 1977a). In general, the rate of infusion was about 3.1 mEq/kg/hr. Animals were restrained, and the femoral artery and vein were cannulated on one side. Indwelling catheters were fixed; the venous catheter was used for the infusion, and the arterial catheter was employed to sample for arterial blood formate, formaldehyde, pH, and pCO₂. Bicarbonate values were determined from arterial blood pH and pCO₂, according to the Henderson-Hasselbalch relationship. Formate was determined by the method described by Makar *et al.* (1975). Formaldehyde measurements were performed by withdrawing blood samples into syringes which contained solutions of semicarbazide, according to methods described by Tephly *et al.* (1961) and McMartin *et al.* (1977b). The animals were allowed to have fruit and water. Cerebrospinal fluid was taken prior to sacrifice for analysis of formate and formaldehyde. Pupillary reflexes were tested periodically throughout the experiment, and fundus photography was performed as described previously (Hayreh *et al.*, 1977). Four formate-intoxicated monkeys and two control monkeys were employed in studies where histopathological evaluation of the retina, optic disc, and optic nerve was made. Tissue fixation was accomplished by intracardiac perfusion of fixative, as described previously (Baumbach *et al.*, 1977; Martin-Amat *et al.*, 1977b). Histological analyses were performed as described by the previously mentioned investigators.

RESULTS

All findings coincided with those described previously when methanol was administered to monkeys (McMartin *et al.*, 1975; Martin-Amat *et al.*, 1977a; Hayreh *et al.*, 1977; Baumbach *et al.*, 1977). After 10 hr all experimental animals accumulated formate to blood concentrations ranging between 10 and 30 mEq/liter. In general, there was a correlation between rate of onset, degree of ocular toxicity, and concentration of formate in the blood. Generally, the onset of ocular toxicity occurred more rapidly in the formate-treated animals than in animals which had received methanol in previous studies (Martin-Amat *et al.*, 1977a; Hayreh *et al.*, 1977). Blood pH values were maintained between 7.4 and 7.6 in all experimental animals. Table 1 shows the maximal value of formate in the blood achieved in various animals treated with formate, as well

OCULAR FUNCTION AND OPHTHALMOSC

Animal	Time after initiation of formate infusion (hr)	Maximum blood conc (mEq/l)
1	39	30
2	50	30
3	41	20
4	25	10

* Monkeys received formate (3.1 mEq/kg/hr)

as the clinical observations for each formate-treated animal, and in monkeys between 24 and 48 hr after the onset of

Figures 1 and 2 are fundus photographs taken at 24 and 48 hr after formate treatment. The normal appearance of the optic nerve head was as marked as that seen in methanol-intoxicated monkeys (Martin-Amat *et al.*, 1977).



FIG. 1. Fundus photograph of rhesus monkey showing normal appearance of the optic nerve head (C)

Iowa City

*

**

TABLE 1
OCULAR FUNCTION AND OPHTHALMOSCOPIC CHANGES IN FORMATE-INTOXICATED RHESUS MONKEYS^a

Animal	Time after initiation of formate infusion (hr)	Maximum formate blood concentrations (mEq/liter)	Clinical observations	
			Pupillary reflex	Fundus changes
1	39	34	No response mydriasis 7 mm	Moderate optic disc edema with retinal edema
2	50	30	No response mydriasis 8 mm	Severe optic disc edema
3	41	20	No response mydriasis 8 mm	Severe optic disc edema
4	25	12	Normal 3 mm	Moderate optic disc edema

^a Monkeys received formate (3.1 mEq/kg/hr) intravenously.

as the clinical observations for each animal. Pupillary reflexes were rapidly altered in formate-treated animals, and in most animals no response to light was observed between 24 and 48 hr after the onset of formate infusion.

Figures 1 and 2 are fundus photographs of a representative monkey, 1 week prior to and 24 hr after formate treatment. Marked optic disc edema was observed (Fig. 2) and was as marked as that seen in methanol-treated monkeys (Fig. 3). The findings were essentially identical to those observed previously (Hayreh *et al.*, 1977; Baumbach *et al.*, 1977).

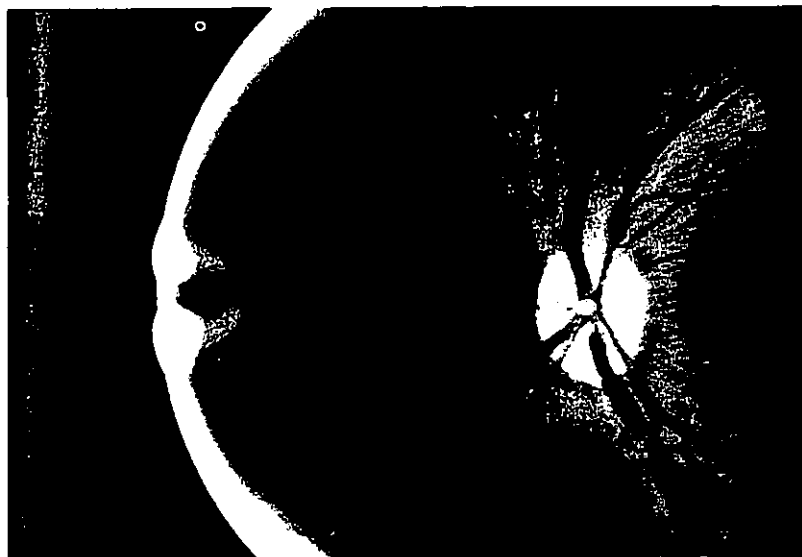

FIG. 1. Fundus photograph of rhesus monkey, 1 week prior to initiation of formate administration. Notice normal appearance of the optic nerve head (optic disc), vessels, and retina.

Light microscopic evaluation of the optic disc area revealed severe edema localized mainly in the prelaminar region. The lesions were mainly in the central portion of the proximal part of the nerve, but, in general, the lesions did not continue to the distal part

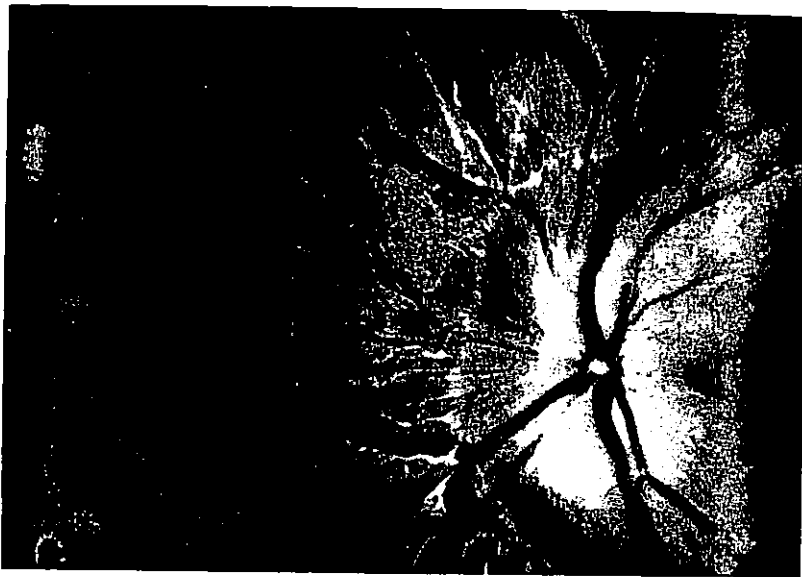


FIG. 2. Fundus photograph of rhesus monkey 41 hr after initiation of formate administration (same animal as in Fig. 1). Blurring of the optic disc (optic disc edema) is evident.

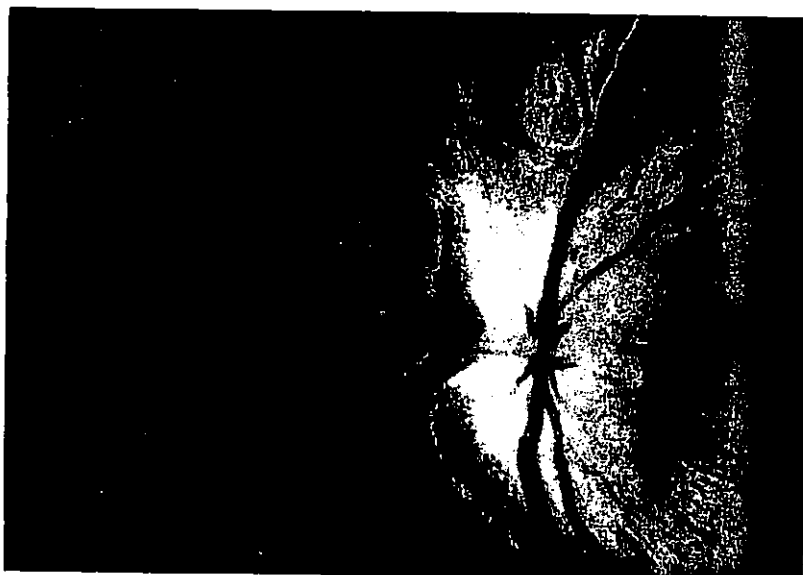


FIG. 3. Fundus photograph of methanol-intoxicated rhesus monkey 67 hr after initiation of methanol administration as described by Martin-Amat *et al.* (1977a). As in Fig. 2 there is blurring of the optic disc (less extensive).

of the optic nerve. These results are in agreement with those of Baumbach *et al.* (1977), who reported that the optic ganglion cell layer, was completely normal in methanol-poisoned monkeys (Baumbach *et al.*, 1977).



FIG. 4. Light microscopic longitudinal section of the optic nerve head showing a normal appearance in the optic nerve head.

DI

McMartin *et al.* (1977b) and Makar *et al.* (1977c) reported that in severe methanol poisoning, where formaldehyde appeared in blood, both formaldehyde and formic acid were present in methanol-poisoned monkeys (animals which had a high level of formaldehyde accumulation of formaldehyde was observed (McMartin *et al.*, 1977b). These observations may not be responsible for the ocular toxicity (McMartin *et al.*, 1977b). It was expected that formaldehyde would be present *in vivo*, since formate was rapidly metabolized to formaldehyde.

of the optic nerve. These results are seen in Figs. 4 and 5. The retina, including the ganglion cell layer, was completely normal, as was described in methanol-poisoned monkeys (Baumbach *et al.*, 1977).




FIG. 4. Light microscopic longitudinal section of the optic nerve head of an untreated rhesus monkey. Notice normal appearance in the optic nerve head. Magnification, 160x.

DISCUSSION

McMartin *et al.* (1977b) and Makar and Tephly (1977) showed that, in animals with severe methanol poisoning, where formate blood concentrations were high, no formaldehyde appeared in blood, body fluids, or tissues. Even in folate-deficient, methanol-poisoned monkeys (animals which are profoundly sensitive to methanol), no accumulation of formaldehyde was observed in any sample of body fluid or tissue (McMartin *et al.*, 1977b). These observations led to the conclusion that formaldehyde may not be responsible for the ocular toxicity seen in methanol poisoning (Martin-Amat *et al.*, 1977b). It was expected that formate would not be converted to formaldehyde *in vivo*, since formate was rapidly metabolized to CO₂ in the rat (Palese and Tephly, 1975)

odd statement
what about metabolism?
Iowa City

edema localized
l portion of the
o the distal part



inistration (same



of methanol
the optic disc

and, in the monkey, the pathway for formate oxidation to CO_2 , appeared to be similar to that observed in the rat, although somewhat reduced quantitatively (McMartin *et al.*, 1977a). Formaldehyde was not detected in any body fluids or tissues such as blood, cerebrospinal fluid, or liver. These results were expected and point again to the inability to associate optic nerve toxicity seen in methanol poisoning with an excess, or presence, of formaldehyde. Formate does produce optic nerve toxicity, as seen in methanol



FIG. 5. Light microscopic longitudinal section of the optic nerve head of a formate-intoxicated rhesus monkey 53 hr after initiation of formate administration. Empty round spaces are evident. Magnification, 160x.

poisoning in the monkey. This was surprising but consistent. Formate produces its toxicity apart from the acidotic state which accompanies and complicates the methanol poisoning syndrome in monkeys and humans. Thus, formate infusion at physiological pH leads to pupillary reflex changes, optic disc edema, and optic nerve lesions characterized by intraaxonal swelling and mitochondrial disruption. Recent evidence suggests that optic disc edema originated by different causes is related to the status of axoplasmic flow (Minckler *et al.*, 1976; Tso and Hayreh, 1977).

The mechanism of formate toxicity is unknown, but a working hypothesis has been

suggested (Martin-Amat *et al.*, 1977). Oxidative phosphorylation by formate activity. Recent observations (Nicolini *et al.*, 1977) showing that inhibiting cytochrome oxidase activity in this study appear to be high (5–30%) in the cerebrospinal fluid in the curare-anesthetized rhesus monkeys (Martin-Amat *et al.*, 1977). Inhibition of energy processes by formate activity, may be directly or indirectly, in both methanol-poisoned and formate-

- BAUMBACH, G., CANCELLA, P., MARTIN-AMAT, G., A. B., HAYREH, M. S., AND HAYREH, S. S. (1977). Ocular morphology in the methanol-poisoned monkey. *Arch. Ophthalmol.* 95, 1865.
- BENTON, C. D., AND CALHOUN, F. P. (1977). Report of catastrophe involving 320 people. *Arch. Ophthalmol.* 95, 1865.
- CLAY, K. L., MURPHY, R. C., AND WATSON, J. (1977). The primates: Analysis of metabolic acidosis. *Arch. Ophthalmol.* 95, 1865.
- GILGER, A. P., AND POTTS, A. M. (1955). Acidosis in experimental methanol poisoning. *Arch. Ophthalmol.* 53, 1865.
- HAYREH, M. S., HAYREH, S. S., BAUMBACH, G., R., McMARTIN, K. E., AND MAKAR, A. B. (1977). *Arch. Ophthalmol.* 95, 1851–1858.
- MAKAR, A. B., McMARTIN, K. E., PALFALVI, Z., AND HAYREH, S. S. (1977). Body fluids: Application in methanol poisoning. *Arch. Ophthalmol.* 95, 1865.
- MAKAR, A. B. AND TEPHLY, T. R. (1977). Production of methanol poisoning in rhesus monkeys. *Arch. Ophthalmol.* 95, 1865.
- MARTIN-AMAT, G., TEPHLY, T. R., HAYREH, S. S., BAUMBACH, G., AND HAYREH, M. S. (1977). Development of a model for ocular toxicity in methanol poisoning. *Arch. Ophthalmol.* 95, 1847–1850.
- MARTIN-AMAT, G., McMARTIN, K. E., HAYREH, M. S., HAYREH, S. S., AND TEPHLY, T. R. (1977). Methanol poisoning. In *Alcohol and Aldehyde Metabolism* (H. Drott, and B. Chance, eds.), Vol. II. New York: Academic Press, 1865.
- MCMARTIN, K. E., MAKAR, A. B., MARTIN-AMAT, G., HAYREH, M. S., AND TEPHLY, T. R. (1977). Methanol poisoning: I, The role of formate metabolism and the reversal by 4-methylpyridine. *Arch. Ophthalmol.* 95, 1865.
- MCMARTIN, K. E., MARTIN-AMAT, G., HAYREH, M. S., AND TEPHLY, T. R. (1977). Methanol poisoning: V, Role of formate metabolism. *Arch. Ophthalmol.* 95, 1865.
- MCMARTIN, K. E., MARTIN-AMAT, G., HAYREH, M. S., AND TEPHLY, T. R. (1977). Methanol poisoning: Role of formate metabolism. *Systems* (R. G. Thurman, J. R. Williams, eds.), Vol. 1, pp. 429–440, Academic Press, New York.
- MINCKLER, D. S., TSO, M. O. M., AND HAYREH, S. S. (1976). An autoradiographic study of axoplasmic flow in the optic nerve during hypotony, increased intraocular pressure, and formate poisoning. *Arch. Ophthalmol.* 94, 757.

suggested (Martin-Amat *et al.*, 1977a). The explanation centers around the inhibition of oxidative phosphorylation by formate based on the inhibition of cytochrome oxidase activity. Recent observations (Nicholls, 1975) indicate that formate is capable of inhibiting cytochrome oxidase activity. Although inhibitory concentrations of formate in this study appear to be high (5–30 mM), concentrations of formate achieved in blood and cerebrospinal fluid in the current studies and in previous methanol-intoxicated rhesus monkeys (Martin-Amat *et al.*, 1977a) appear to be within the limits used. The inhibition of energy processes by formate, through effects on cytochrome oxidase activity, may be directly or indirectly involved in producing the ocular toxicity seen in both methanol-poisoned and formate-intoxicated monkeys.

REFERENCES

- BAUMBACH, G., CANCELLA, P., MARTIN-AMAT, G., TEPHLY, T. R., McMARTIN, K. E., MAKAR, A. B., HAYREH, M. S., AND HAYREH, S. S. (1977). Methanol poisoning: IV, Alterations of the ocular morphology in the methanol-poisoned rhesus monkey. *Arch. Ophthalmol.* **95**, 1859–1865.
- BENTON, C. D., AND CALHOUN, F. P. (1953). The ocular effects of methyl alcohol poisoning: Report of catastrophe involving 320 persons. *Amer. J. Ophthalmol.* **36**, 1677–1685.
- CLAY, K. L., MURPHY, R. C., AND WATKINS, W. D. (1975). Experimental methanol toxicity in the primates: Analysis of metabolic acidosis. *Toxicol. Appl. Pharmacol.* **34**, 49–61.
- GILGER, A. P., AND POTTS, A. M. (1955). Studies on the visual toxicity of methanol: V, The role of acidosis in experimental methanol poisoning. *Amer. J. Ophthalmol.* **39**, 63–86.
- HAYREH, M. S., HAYREH, S. S., BAUMBACH, G., CANCELLA, P., MARTIN-AMAT, G., TEPHLY, T. R., McMARTIN, K. E., AND MAKAR, A. B. (1977). Methanol poisoning: III, Ocular toxicity. *Arch. Ophthalmol.* **95**, 1851–1858.
- * MAKAR, A. B., McMARTIN, K. E., PALESE, M., AND TEPHLY, T. R. (1975). Formate assay in body fluids: Application in methanol poisoning. *Biochem. Med.* **13**, 117–126.
- MAKAR, A. B. AND TEPHLY, T. R. (1977). Methanol poisoning: VI, Role of folic acid in the production of methanol poisoning in rat. *J. Toxicol. Environ. Health* **2**, 1201–1209.
- MARTIN-AMAT, G., TEPHLY, T. R., McMARTIN, K. E., MAKAR, A. B., HAYREH, M. S., HAYREH, S. S., BAUMBACH, G., AND CANCELLA, P. (1977a). Methanol poisoning: II, Development of a model for ocular toxicity in methanol poisoning using the rhesus monkey. *Arch. Ophthalmol.* **95**, 1847–1850.
- MARTIN-AMAT, G., McMARTIN, K. E., MAKAR, A. B., BAUMBACH, G., CANCELLA, P., HAYREH, M. S., HAYREH, S. S., AND TEPHLY, T. R. (1977b). The monkey as a model in methanol poisoning. In *Alcohol and Aldehyde Metabolizing Systems* (R. G. Thurman, J. R. Williamson, H. Drott, and B. Chance, eds.), Vol. II, pp. 419–428, Academic Press, New York, 1977.
- McMARTIN, K. E., MAKAR, A. B., MARTIN-AMAT, G., PALESE, M., AND TEPHLY, T. R. (1975). Methanol poisoning: I, The role of formic acid in the development of metabolic acidosis in the monkey and the reversal by 4-methylpyrazole. *Biochem. Med.* **13**, 319–333.
- McMARTIN, K. E., MARTIN-AMAT, G., MAKAR, A. B., AND TEPHLY, T. R. (1977a). Methanol poisoning: V, Role of formate metabolism in the monkey. *J. Pharmacol. Exp. Therap.* **201**, 564–572.
- McMARTIN, K. E., MARTIN-AMAT, G., MAKAR, A. B., AND TEPHLY, T. R. (1977b). Methanol poisoning: Role of formate metabolism in the monkey. In *Alcohol and Aldehyde Metabolizing Systems* (R. G. Thurman, J. R. Williamson, H. Drott, and B. Chance, eds.), Vol. II, pp. 429–440, Academic Press, New York, 1977.
- MINCKLER, D. S., TSO, M. O. M., AND ZIMMERMAN, L. E. (1976). A light microscopic autoradiographic study of axoplasmic transport in the optic nerve head during ocular hypotony, increased intraocular pressure and papilledema. *Amer. J. Ophthalmol.* **82**, 742–757.

- NICHOLLS, P. (1975). Formate as an inhibitor of cytochrome *c* oxidase. *Biochem. Biophys. Res. Commun.* **67**, 610-616.
- PALESE, M., AND TEPHLY, T. R. (1975). Metabolism of formate in the rat. *J. Toxicol. Environ. Health* **1**, 13-24.
- RÖE, O. (1943). Clinical investigation of methyl alcohol poisoning with special reference to the pathogenesis and treatment of amblyopia. *Acta Med. Scand.* **113**, 558-608.
- TEPHLY, T. R., PARKS, R. E., AND MANNERING, G. J. (1961). The effect of 3-amino-1,2,4-triazole (AT) and sodium tungstate on the peroxidative metabolism of methanol. *J. Pharmacol. Exp. Ther.* **131**, 147-151.
- TSO, M. O. M., AND HAYREH, S. S. (1977). Optic disc edema in raised intracranial pressure: IV. Axoplasmic transport in experimental papilledema. *Arch. Ophthalmol.* **95**, 1458-1462.

SHORT

Acute Toxicity of Polychlorinated

Acute Toxicity of Polychlorinated
Toxicol. Appl. Pharmacol. **45**, 209-
given synthesized polychlorinated dibenzofurans.
The oral LD₅₀ was approximately 200 mg/kg. Mice
died, hepatomegaly and atrophy of the liver, and
and dermal alterations also occurred. Necrotic
necrotic foci accompanied by cellular necrosis were
Ultrastructural alterations of hepatocytes included
in lipid droplets and moderate hyperplasia of the
these results, it was concluded that the toxicity was
associated with 2,3,7,8-tetrachlorodibenzofurans.

Since reports of the identification of polychlorinated dibenzofuran
impurities of two European polychlorinated biphenyls (PCBs) and
American PCB (Bowes *et al.*, 1975) and polychlorinated dibenzofuran
Nagayama *et al.*, 1975), as well as polychlorinated dibenzofuran in
rice oil (Nagayama *et al.*, 1975), the presence of polychlorinated dibenzofuran
has become of great concern. Rice oil has been found to contain
about 10 ppb in the adipose tissue of mice fed with rice oil. The
commercial rice oil contaminated with polychlorinated dibenzofuran
(Nagayama *et al.*, 1977), and was found to be toxic to mice (Nagayama
normal subjects at a concentration of 100 mg/kg (Nagayama *et al.*,
1977). These findings indicate a need for further studies on
and the PCDF contaminants.

While many toxicological studies have been conducted on polychlorinated
dibenzo-*p*-dioxins (PCDD), which are known to be highly toxic, only a
few reports on the toxicity of pure polychlorinated dibenzofurans
undertaken, therefore, to investigate the acute toxicity of polychlorinated

The PCDF used was synthesized from 2,3,7,8-tetrachlorodibenzofuran, 54%
42% tetrachlorodibenzofurans, 54% tetrachlorodibenzofurans, 54%
benzofurans, by gas chromatography-mass spectrometry (Nagayama
1975). Olive oil solutions of the test material were prepared (Nagayama
1975).

Sixty 8-week-old CF-1 mice, male, were divided into three groups and
single doses of PCDF via gavage (100 mg/kg), or intraperitoneally (10 to
100 mg/kg).